

Intravitreal bevacizumab improves the clearance of vitreous haemorrhage and visual outcomes in patients with proliferative diabetic retinopathy

Joonas Wirkkala,¹ Risto Bloigu,² Nina Maria Hautala ¹

To cite: Wirkkala J, Bloigu R, Hautala NM. Intravitreal bevacizumab improves the clearance of vitreous haemorrhage and visual outcomes in patients with proliferative diabetic retinopathy. *BMJ Open Ophthalmology* 2019;4:e000390. doi:10.1136/bmjophth-2019-000390

Received 28 August 2019
Revised 14 October 2019
Accepted 9 November 2019

ABSTRACT

Objective To evaluate the occurrence of vitreous haemorrhage (VH) secondary to proliferative diabetic retinopathy (PDR) and the efficacy of intravitreal bevacizumab (IVB) for VH in 5-year real-life data.

Methods and analysis 850 adult patients with type 1 (T1D) or type 2 diabetes (T2D) with PDR were screened for VH. The effect of IVB was evaluated by the clearance of VH and the change in best corrected visual acuity (BCVA). The rates of VHs, reinjections, macular oedema, complications, additional treatments and outcomes of spontaneous resorption, panretinal photocoagulation or pars plana vitrectomy (PPV) for VH were also investigated.

Results VH occurred in 16% of patients with T1D and 9% of patients with T2D with PDR. 336 VHs in 140 eyes of 103 patients were documented. VH was cleared in 92% of cases in less than 3 months by the initial IVB. IVB was superior to other treatment methods in shortening the time for clearance of VH (Kaplan-Meier, $p < 0.0001$). The average rate of IVB reinjections was 1.7 ± 1.1 and the reinjection interval was 7.2 ± 3.9 weeks. BCVA increased 0.73 ± 0.04 logarithm of the minimum angle of resolution units after IVB (generalised estimating equations, $p = 0.0004$). In 5 years, the patients had 2.2 ± 2.7 recurrence of VHs. A simultaneous 72% decrease in the rate of PPVs was documented ($p < 0.0001$).

Conclusion VH occurs mostly in patients with T1D. The therapeutic effect of IVB for VH was significant and led to improved clearance of VH and visual outcome. Moreover, IVB prevented persistent and recurrent VHs and decreased the need for costly PPV.

Key messages

What is already known about this subject?

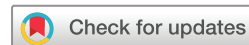- ▶ Vitreous haemorrhage is a complication of proliferative diabetic retinopathy.

What are the new findings?

- ▶ The clearance of haemorrhage and visual outcomes was improved by intravitreal bevacizumab. It also prevented rebleedings and diminished the need for costly vitrectomies.

How might these results change the focus of research or clinical practice?

- ▶ Thus, intravitreal bevacizumab might be considered as a cost-effective treatment for vitreous haemorrhage in patients with diabetes.



© Author(s) (or their employer(s)) 2019. Re-use permitted under CC BY-NC. No commercial re-use. See rights and permissions. Published by BMJ.

¹Department of Ophthalmology, University of Oulu and Oulu University Hospital, Oulu, Finland

²Medical Informatics Group, University of Oulu, Oulu, Finland

Correspondence to

Dr Nina Maria Hautala; nina.hautala@oulu.fi

INTRODUCTION

Diabetes has become a major health issue worldwide. The International Diabetes Federation has estimated that there will be over 640 million people with diabetes in the world by 2040, in comparison to 415 million in 2015.¹ Ocular complications are common in diabetes and especially proliferative diabetic retinopathy (PDR) and diabetic macular oedema (DME) may lead to severe visual loss or even to blindness.² Due to a global increase in the prevalence of diabetes, also the number of patients with diabetic retinopathy (DR) or

vision-threatening DR is estimated to triple from 2005 to 2050.³

PDR is characterised by retinal neovascularisation (NV) at the disc or elsewhere in the retina and can be complicated by vitreous haemorrhage (VH) or tractional retinal detachment (TRD). Several studies have shown that increased levels of vascular endothelial growth factor (VEGF) play a role in the development of retinal NV, as well as in retinal vascular leakage related to PDR and DME.^{4–6}

Panretinal photocoagulation (PRP) has been the golden standard for treating PDR for decades. The Early Treatment Diabetic Research Study concluded that PRP reduces the risk of severe visual loss and slows down the progress of PDR.⁷ PRP induces the regression of retinal NV by decreasing the intravitreal level of VEGF.⁵ VH often prolongs without spontaneous resorption and surgical pars plana vitrectomy (PPV) may be needed. Alternatively, intravitreal anti-VEGF agents may be applied, since anti-VEGF therapy used with PRP or as monotherapy is efficient in treating PDR,^{8–12} iris NV¹³ and VH.^{14–17}

The present 5-year real-life study evaluated the rate of VH in the diabetic population and the clinical effect of intravitreal bevacizumab (IVB) in the clearance of VH, visual outcomes, number of injections needed for resorption of VH, time interval of the reinjections and the frequency of recurrent VH in patients with complicated PDR.

MATERIALS AND METHODS

Patient selection

This study was carried out in Oulu University Hospital. The retrospective interventional case series was performed on all adult patients who presented at Oulu University Hospital with either type 1 (T1D) or type 2 diabetes (T2D) complicated by VH due to PDR between 1 January 2011 and 31 December 2015. The hospital's electronic patient database was used to search the potential study patients by using the International Classification of Diseases diagnose codes for diabetes, PDR and VH. When the fundus of a patient could not be visualised due to VH, an ultrasonography examination was performed in order to exclude any tractional or other retinal detachment that would have been contraindicated for intravitreal anti-VEGF treatment. Only patients with naive eyes for PPV were included for the study and those with a history of prior PPV before beginning of the follow-up period were excluded from the statistical analysis (n=4). Exclusion was also made if the follow-up period was less than a 1 year (n=3). Subjects who had VH for reasons other than PDR (eg, retinal vein occlusion, retinal detachment or retinal breaks) were also excluded. After identifying the potential study subjects, a chart review of the patients' demographic information was made, consisting of treatments used for VH (IVB, PRP, PPV) and spontaneous resorption, best corrected visual acuity (BCVA), intraocular pressure, iris NV and lens status. Patient records were also reviewed for dates of IVB, PRP, PPV, spontaneous resorption and the status of each VH during the study period. BCVA measurements were converted to a logarithm of the minimum angle of resolution (logMAR) for analysis.

Patient involvement

Patients were not directly involved in the design of this study.

Statistical analysis

The IBM SPSS Statistics V.23 was used for the statistical analysis. In our study, multiple occurrences (VH) were found in a patient in one eye. In order to take the correlation of a specific patient's repeated VHs into consideration, generalised estimation equation with exchangeable structure was used to analyse differences in the time of clearance of VHs with different treatment methods and to evaluate BCVA at the baseline and after. Four models were used to assess covariates: diabetes type, prior PRP, prior IVB and PPV to see if PPV for VH during the follow-up period had any effect to the study

Table 1 Baseline features of patients with vitreous haemorrhage and their ocular parameters on the affected eye

Characteristics	T1D	T2D	All
Number of patients	57	46	103
Gender			
Female	32	17	49
Male	25	29	54
Age (years, mean±SD)	44±13	66±7	54±15
PRP prior to VH	55	36	91
No eyes with VH	76	64	140
Eyes with iris neovascularisation	6	14	20
Lens status of the affected eye			
Phakic	36	7	43
Cataract	9	14	23
IOL	30	43	73
Aphakic	1	0	1
Eyes with macular oedema	12	23	35
Naive eyes for IVB	68	56	124

IOL, intraocular lens; IVB, intravitreal bevacizumab; PRP, panretinal photocoagulation; T1/2D, type 1/2 diabetes; VH, vitreous haemorrhage.

outcomes, also the baseline BCVA was taken into consideration in the statistical analysis. Kaplan-Meier analysis was performed to compare the efficiency of anti-VEGF treatment versus other treatment modalities. The χ^2 test was used for identifying differences between categorical variables. T-test was used for finding the differences in continuous variables between two groups. The Pearson correlation was calculated to find correlations between continuous variables.

RESULTS

During the 5-year study period, a total of 850 patients with either T1D (n=351) or T2D (n=499) were diagnosed with PDR and followed up in Oulu University Hospital. The baseline characteristics of the study population are shown in table 1. There were 49 females and 54 males with VH secondary to PDR attending the study. The age of the patients ranged between 23 and 85 years, whereas the average age for patients with T1D was 44±13 and 66±7 years for patients with T2D.

Sixteen per cent of the patients with T1D and 9% of the patients with T2D developed at least one occurrence of VH secondary to PDR in the total of 140 eyes. Prior PRP before any VH had been performed in 88% of the patients with VH (91 patients, 121 eyes). There was a total of 336 incidences of VHs in the study population during the follow-up. Two hundred and twenty-four VHs (67%) in 97 eyes were treated initially by IVB. The first treatment choice was waiting for spontaneous resorption of VH in an additional 14%, PRP in 6% and PPV in 13% of the cases. The decision of the primary treatment was made

Table 2 Result summary of intravitreal bevacizumab (IVB), panretinal photocoagulation (PRP), pars plana vitrectomy (PPV) or observation performed on patients with vitreous haemorrhage (VH) in a real-life setting

	IVB	PRP	PPV	Observation
No VHs	224	22	43	47
BCVA (logMAR*)				
Baseline	1.15±0.70	0.55±0.57	0.39±0.43	0.24±0.33
After	0.42±0.42	0.19±0.21	0.75±0.62	0.26±0.34
VH duration (days*)	57±46	76±54	103±84	81±42
IOP (mm Hg*)				
Baseline	16.7±4.9	17.2±3.3	16.7±9.0	17.0±5.9
After	16.3±4.5	15.7±3.7	14.5±4.3	16.4±4.1

*Mean±SD.

BCVA, best corrected visual acuity; IOP, intraocular pressure; logMAR, logarithm of the minimum angle of resolution.

by a retina specialist according to Current Care Guidelines for DR¹⁸ and the clinical status of the retina and vitreous. The patients with very mild VH and previous PRP were likely to be observed. PRP was option for those with mild VH, no completed or prior PRP and a relatively good fundus visibility. The patients with more dense VH lowering their visual acuity were treated mainly by IVB if there were no contraindications for intravitreal treatment, such as retinal traction, ocular infections or recent cardiovascular or cerebral disorders. PPV was a choice of treatment if there was a potential risk for retinal traction or other complications.

In 14 cases of the total of 336 VHs (4%), 14 different patients (14% of the total of 103 patients) had contraindications for IVB. These 14 cases with contraindications consisted of pregnancy (3 patients), refusal of patient (3 patients), acute ocular infection (3 patients) and preceding cardiovascular complications (5 patients).

VH was cleared in 92% and 61% cases in less than 3 months by IVB or other treatment modalities, respectively ($p<0.0001$, χ^2 test). Several patients reported that the resorption of VH occurred even within a few days to 1–2 weeks after the IVB. The time from the beginning of VH to its clearance was 57±46 days by IVB, 76±54 days by PRP, 103±84 by performing PPV and 81±42 by observation in a real-life setting (table 2). As seen in figure 1, the median estimate for clearance of VH after the diagnosis of a new VH was 46±2 days in the IVB group and 70±6 days in patients treated by other treatment modalities (Kaplan-Meier, 95% CI 42.3 to 49.7, $p<0.0001$). Figure 2 shows the clearance of VH and rapid inactivation of NV after IVB.

The final BCVA measured after the resolution of VH improved by ≥15 letters in 66% and in 59% of cases by initial IVB or other treatment modalities, respectively (table 2). IVB resulted significant improvement of BCVA of 0.73±0.04 logMAR units (7 Snellen lines) in average (generalised estimating equations, $p=0.0004$). The

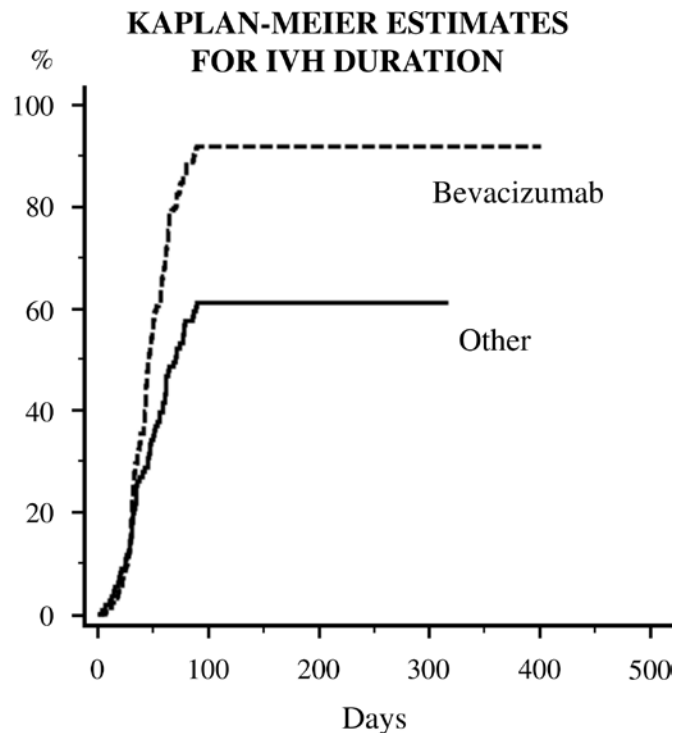


Figure 1 Kaplan-Meier shows the clearance of vitreous haemorrhage (VH) with intravitreal bevacizumab and other treatments (pars plana vitrectomy, panretinal photocoagulation, observation) at 3 months. The diagnosis of VH was considered as the baseline point. IVH, intraventricular haemorrhage.

baseline conditions, diabetes type ($E=0.03$, $SD \pm 0.02$, $p=0.223$), prior PRP ($E=-0.01$, $SD \pm 0.01$, $p=0.538$), prior IVB ($E=0.07$, $SD \pm 0.04$, $p=0.073$) or prior PPV ($E=0.10$, $SD \pm 0.08$, $p=0.228$) were not significantly associated with BCVA improvement.

During the follow-up, a total of 376 injections were applied. The average rate of IVB injections for one VH was 1.7±1.1 (range from 1 to 7) and the reinjection interval 7.2±3.9 weeks. The study patients in all groups in total had 2.2±2.7 recurrence of VH in 5 years. None of the study patients had serious adverse effects of IVB or developed TRD.

DISCUSSION

In the 1980s, the Diabetic Retinopathy Vitrectomy Study showed that 80% of VHs secondary to PDR did not clear spontaneously and required surgical intervention. The management of diabetes mellitus along with treatments for PDR and VHs has improved thereafter. Still, VH may prolong without spontaneous resorption and PPV may be required. PRP has been the golden standard for treating PDR for decades. Although successful at preventing blindness, however, PRP commonly causes retinal damage and visual side effects, including constricted visual fields, reduced visual acuity, altered colour vision, impaired dark adaptation and decreased contrast sensitivity.^{19 20} Moreover, PRP may be unavailable for patients with VH due to poor retinal visibility. Distinguishing the effects of

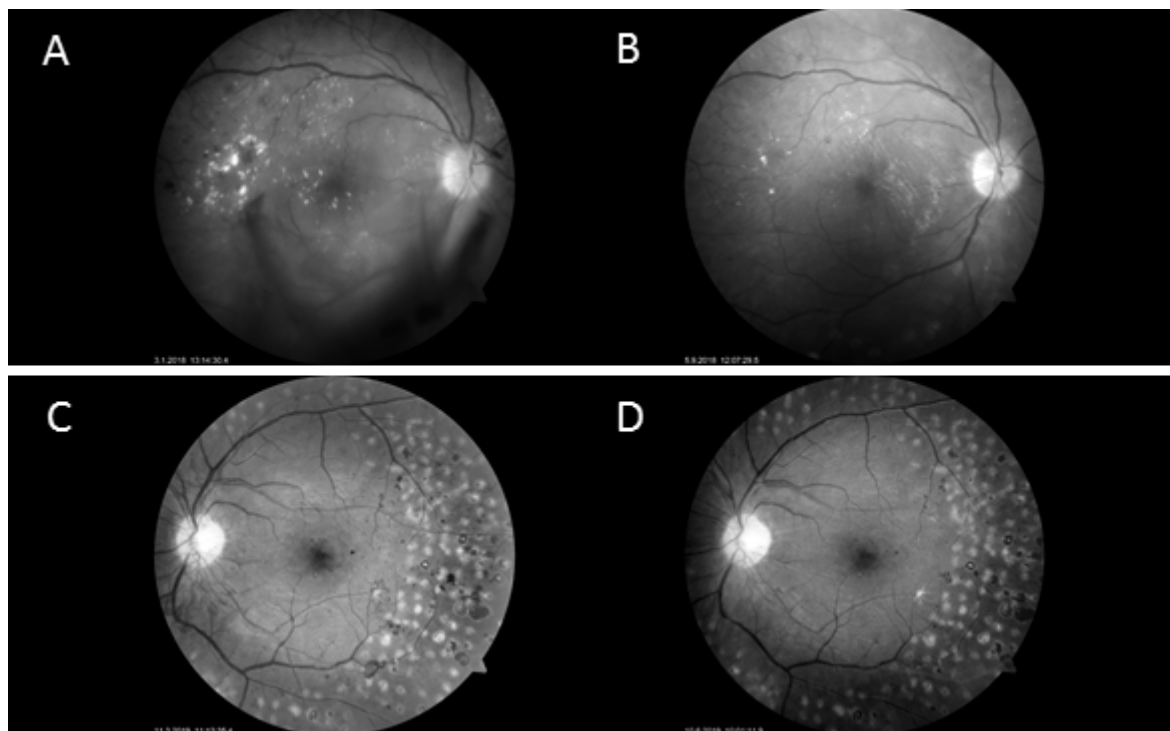


Figure 2 Vitreous haemorrhage and maculopathy in a 54-year-old man with type 1 diabetes are shown (A) before and (B) after three intravitreal bevacizumab injections. (C) Neovascularisation at disc and retina were rapidly inactivated (D) after a single intravitreal bevacizumab injection in a 28-year-old man with type 1 diabetes.

PDR and PRP has thus increased the need of restorative vision therapies for patients with advanced DR. There is good evidence of anti-VEGF therapy being used with PRP or as monotherapy to treat PDR and its complications.^{8–17} CLARITY (Clinical efficacy and mechanistic evaluation of aflibercept for proliferative diabetic retinopathy) study has shown that anti-VEGF therapy was superior to PRP in terms of improvement in BCVA in patients with PDR,²¹ suggesting that in addition to PRP, anti-VEGF should be used more widely as a conjunctive treatment for PDR to avoid the development of complications such as VH or TRD. The present study evaluated the efficacy of IVB, spontaneous resorption, PRP or PPV for VH secondary to PDR in real-life data.

Sixteen per cent of patients with T1D and nine per cent of patients with T2D with PDR developed at least one episode of VH during 5 years. This is in line with the previous studies indicating that PDR and its complications are more common in patients with T1D compared with those with T2D.^{22–24} Eighty-eight per cent of the study patients with VH had had previous PRP. The 67% initial rate of IVB with VH secondary to PDR in the current study is high compared with that of one-third reported previously.¹⁷ Our experience from the clinical setting since 2006 has suggested the usefulness and safety of anti-VEGF agents in the treatment of VH. The complete resolution of VH by IVB was achieved in 92% of cases in less than 3 months, and even within a few days to 1–2 weeks in several patients. To support this, diminished leakage of NV at 24 hours after IVB has been documented.²⁵ In agreement with our results, Sinawat *et al* have reported

that new dense VH cleared completely by IVB in 39%, 50% and 72% of 18 eyes with previous PRP after 6 weeks, 6 months and 12 months, respectively.²⁶ More significant regression of retinal NV after IVB in patients with PDR and previous PRP has been documented compared with treatment-naïve patients,⁸ suggesting that IVB may be a potential adjuvant to PRP for PDR. Also, in contrast to PRP, anti-VEGF agents lower the rate of development or deteriorating of DME concomitant with PDR.²⁷

The initial IVB for VH resulted in significantly better visual outcomes in comparison to PRP, PPV or observation alone despite the worse baseline BCVA in IVB group versus other interventions. This may result from the resolution of possible subsequent and subclinical DME in addition to improved clearance of the vitreous cavity by IVB. Prior IVB due to earlier diagnosed DME was not, however, associated with the rate of improvement of BCVA in patients with VH. Improved visual acuity had also been reported in patients with PDR after the repeated anti-VEGF injections^{8,9,28} and even 1 year after IVB for a dense VH.²⁶ In contrast, Parikh *et al* reported no significant difference in BCVA between patients receiving PRP, PPV or IVB at 1 year.¹⁷ The discrepancy between these results may result from the differences in the patient selection including the baseline BCVA, severity of PDR, density of VH and the possible presence of DME or the potential postoperative cataract formation in the PPV group.

The new VH resolved by an average of 1.7 IVB injections in our study. In agreement, Parikh *et al* have documented that VH requires an average of 2 IVB injections and 12% of the cases can be managed even by a single injection.¹⁷

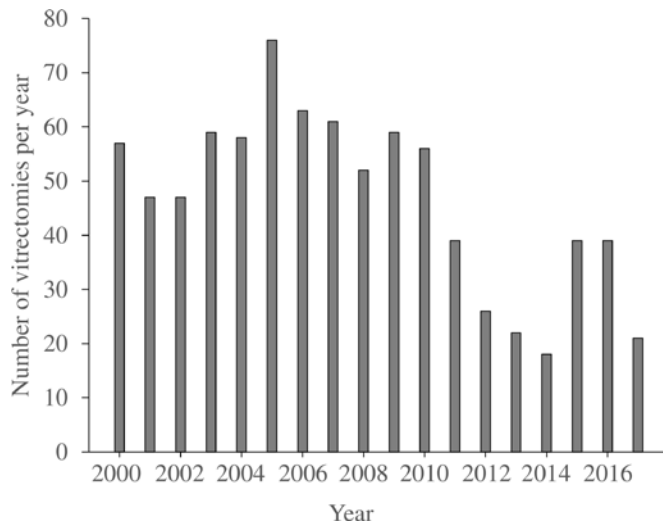


Figure 3 Number of diabetic vitrectomies during the years 2000–2017 in the Oulu University Hospital. Intravitreal bevacizumab treatment for vitreous haemorrhage was initiated in 2006.

This is less than 3.7 intravitreal ranibizumab (IVR) injections for VH or an average of 4 injections needed for regression of retinal NV reported previously.^{8 9 14} It may be assumed that the resolution of a new VH from the bleeding NV requires less IVB injections than the complete regression of any NV at the disc or elsewhere. However, the complete regression of NV would be necessary to lower the risk of rebleeding.

The recurrences of VH have been previously documented in 17%–56% of patients treated initially by anti-VEGF agents during 1 year.^{14 17 26} In our study, the average VH recurrence rate was only 2.2 after initial IVB, which is significantly less compared with PRP or no primary intervention. Thus, the effect of IVB in stabilising DR might be longer than one could assume based on its known biological activity. In agreement, the recurrence of VH has been demonstrated in one-third and in a half of the patients treated by IVR or assigned to observation, respectively.¹⁴ The transient effect of IVB may lead to reactivation of NV and recurrent VH. Multiple injections may thus be needed to prevent further progression of PDR and VH to retain the stable visual function in patients with diabetes. However, our results show that the interval between reinjections may be relatively long.

In a recent study, 19% and 15% of the patients initially treated by IVB required PPV for recurrent VH after 1 or 2 years, respectively, and 4% needed surgery for TRD.¹⁷ Another study reported a 10% rate for PPV after IVB compared with that of 45% in controls.¹⁵ In agreement, a 24% need for PPV with IVR versus a 35% need in the control group has been demonstrated.¹⁴ It has been assumed that even 72% of patients could avoid PPV by receiving IVB timely.²⁶ This emphasises the significant benefit of IVB in patients with PDR who often are high-risk candidates for surgery. In our study, only 7% of the 100 patients treated initially by IVB had PPV during the

study period of 5 years and none developed TRD. The discrepancy in the numbers of PPV and TRD may be explained by patient selection excluding the patients with previous TRD or high risk for developing TRD as contraindication for initial IVB in the current study. During the years 1993–2005, the number of PPVs performed for VHs in patients with diabetes in Oulu University Hospital increased continuously, but the increase ended in 2006 after the initiation of IVB treatment for VHs. Thereafter, the incidence of PPVs for patients with diabetes has declined 72% during 2005–2017 as presented in figure 3 (IRR=0.90, Poisson regression model, 95% CI 0.88 to 0.92, $p<0.0001$, Pearson χ^2).

Lin *et al* have evaluated the cost of PPV, PRP and IVR for the treatment of PDR,²⁹ suggesting that early PPV for the treatment of PDR without DME demonstrates cost-utility-like PRP and more favourable cost utility compared with IVR assuming the need for IVR to be regular and continuous over a lifetime. In contrast to this, our study demonstrates only transient need for IVB for the treatment of VH with only 1.7 injections in average for each VH, and approximately 2 recurrences of VH over the 5-year period. Also, the cost of IVB is usually markedly less than that of ranibizumab or aflibercept. The treatment of VH by IVB may thus be assumed as cost effective and beneficial considering the direct expenses and the potential improvement of the quality of life of an individual patient due to the accelerated clearance of VH and rapid normalisation of visual function.

Several limitations of our study include that it is non-randomised, uncontrolled and retrospective. Due to its retrospective nature, there was also variability in the time the evaluations of the clearance of VH was concluded. However, to our knowledge from most patients, VH had resorbed much faster and earlier than that documented at 3 months. Thus, our results could have more implications without the negative effect of this bias. Another limitation of our study is that there is no commonly used classification for the density of VH. The severity of VH varies from very mild bleeding to dense haemorrhage and thus affects patients' baseline visual acuity and possibly also to treatment outcomes. Thus, the treatment decisions made might be favourable to outcomes of those patients in the observation or PRP group. The strength of the current study is the long follow-up time of the population-based cohort of patients with diabetes and VH, which enables the determination of the rate of VH recurrences and the need for reinjections in a long-time frame.

None of the study patients had serious adverse effects of IVB or developed TRD during the follow-up, although some previous reports have expressed concerns about the formation of TRD according to anti-VEGF use for PDR.^{30 31} Anti-VEGF treatment seems to lead to a rapid regression of retinal NV and resorption of VH, but a more consistent effect on the stabilisation of PDR has been noted in patients treated additionally by PRP.^{8 9} Taken together, our results suggest that IVB provides a

safe, efficient and cost-effective way to treat VH secondary to PDR by speeding up the resolution of VH, reducing the need of surgical interventions, preventing persistent and recurrent VH and leading to overall better visual outcomes in patients with PDR.

Acknowledgements Tapani Palosaari, MD, Ulla Lahtela, MD and Pasi Hägg, MD, PhD are warmly acknowledged for skillfully performing PPVs in Oulu University Hospital.

Contributors All authors have significantly contributed to work: designing the study protocol (all authors), collecting the data (JW, NMH), analysing the results (all authors), preparation of the manuscript (all authors) and reviewing the manuscript (all authors).

Funding The authors have not declared a specific grant for this research from any funding agency in the public, commercial or not-for-profit sectors.

Competing interests None declared.

Patient consent for publication Not required.

Ethics approval The study followed the tenets of the Declaration of Helsinki and it was conducted with the approval of the Oulu University Hospital Research Committee.

Provenance and peer review Not commissioned; externally peer reviewed.

Data availability statement All data relevant to the study are included in the article.

Open access This is an open access article distributed in accordance with the Creative Commons Attribution Non Commercial (CC BY-NC 4.0) license, which permits others to distribute, remix, adapt, build upon this work non-commercially, and license their derivative works on different terms, provided the original work is properly cited, appropriate credit is given, any changes made indicated, and the use is non-commercial. See: <http://creativecommons.org/licenses/by-nc/4.0/>.

ORCID iD

Nina Maria Hautala <http://orcid.org/0000-0001-5454-5602>

REFERENCES

- 1 Cho NH. Q&A: Five questions on the 2015 IDF Diabetes Atlas. *Diabetes Res Clin Pract* 2016;115:157–9.
- 2 Pascolini D, Mariotti SP. Global estimates of visual impairment: 2010. *Br J Ophthalmol* 2012;96:614–8.
- 3 Shah AR, Gardner TW. Diabetic retinopathy: research to clinical practice. *Clin Diabetes Endocrinol* 2017;3.
- 4 Adamis AP, Miller JW, Bernal M-T, et al. Increased vascular endothelial growth factor levels in the vitreous of eyes with proliferative diabetic retinopathy. *Am J Ophthalmol* 1994;118:445–50.
- 5 Aiello LP, Avery RL, Arrigg PG, et al. Vascular endothelial growth factor in ocular fluid of patients with diabetic retinopathy and other retinal disorders. *N Engl J Med* 1994;331:1480–7.
- 6 Wilkinson-Berka J. Vasoactive factors and diabetic retinopathy: vascular endothelial growth factor, cyclooxygenase-2 and nitric oxide. *Curr Pharm Des* 2004;10:3331–48.
- 7 Early Treatment Diabetic Retinopathy Study Research Group. Early photocoagulation for diabetic retinopathy. ETDRS report number 9. *Ophthalmology* 1991;98:766–85.
- 8 Arevalo JF, Lasave AF, Wu L, et al. Intravitreal bevacizumab for proliferative diabetic retinopathy: results from the Pan-American collaborative retina Study Group (PACORES) at 24 months of follow-up. *Retina* 2017;37:334–43.
- 9 Figueira J, Fletcher E, Massin P, et al. Ranibizumab plus Panretinal photocoagulation versus Panretinal photocoagulation alone for high-risk proliferative diabetic retinopathy (Proteus study). *Ophthalmology* 2018;125:691–700.
- 10 Minnella AM, Savastano CM, Ziccardi L, et al. Intravitreal bevacizumab (Avastin®) in proliferative diabetic retinopathy. *Acta Ophthalmol* 2008;86:683–7.
- 11 Moradian S, Ahmadi H, Malihi M, et al. Intravitreal bevacizumab in active progressive proliferative diabetic retinopathy. *Graefes Arch Clin Exp Ophthalmol* 2008;246:1699–705.
- 12 Schmidinger G, Maier N, Bolz M, et al. Repeated intravitreal bevacizumab (Avastin®) treatment of persistent new vessels in proliferative diabetic retinopathy after complete panretinal photocoagulation. *Acta Ophthalmol* 2011;89:76–81.
- 13 Jiang Y, Liang X, Li X, et al. Analysis of the clinical efficacy of intravitreal bevacizumab in the treatment of iris neovascularization caused by proliferative diabetic retinopathy. *Acta Ophthalmol* 2009;87:736–40.
- 14 Chelala E, Nehme J, El Rami H, et al. Efficacy of intravitreal ranibizumab injections in the treatment of vitreous hemorrhage related to proliferative diabetic retinopathy. *Retina* 2018;38:1127–33.
- 15 Huang Y-H, Yeh P-T, Chen M-S, et al. Intravitreal bevacizumab and panretinal photocoagulation for proliferative diabetic retinopathy associated with vitreous hemorrhage. *Retina* 2009;29:1134–40.
- 16 Jonas JB, Libondi T, Von Bartz S, et al. Intravitreal bevacizumab for vitreous haemorrhage. *Acta Ophthalmol* 2008;86:585–6.
- 17 Parikh RN, Traband A, Kolomeyer AM, et al. Intravitreal bevacizumab for the treatment of vitreous hemorrhage due to proliferative diabetic retinopathy. *Am J Ophthalmol* 2017;176:194–202.
- 18 Summanen P, Kallioniemi V, Komulainen J, et al. Update on current care guideline: diabetic retinopathy. *Duodecim* 2015;131:893–4.
- 19 Chhablani J, Sambhana S, Mathai A, et al. Clinical Efficacy of Navigated Panretinal Photocoagulation in Proliferative Diabetic Retinopathy. *Am J Ophthalmol* 2015;159:884–9.
- 20 Hautala N, Siiskonen M, Hannula V, et al. Early glycaemic control for maintaining visual function in type 1 diabetes: the Oulu cohort study of diabetic retinopathy. *Eur J Ophthalmol* 2018;28:684–9.
- 21 Sivaprasad S, Prevost AT, Vasconcelos JC, et al. Clinical efficacy of intravitreal aflibercept versus panretinal photocoagulation for best corrected visual acuity in patients with proliferative diabetic retinopathy at 52 weeks (clarity): a multicentre, single-blinded, randomised, controlled, phase 2B, non-inferiority trial. *The Lancet* 2017;389:2193–203.
- 22 Hautala N, Aikkila R, Korpelainen J, et al. Marked reductions in visual impairment due to diabetic retinopathy achieved by efficient screening and timely treatment. *Acta Ophthalmol* 2014;92:582–7.
- 23 Lee R, Wong TY, Sabanayagam C. Epidemiology of diabetic retinopathy, diabetic macular edema and related vision loss. *Eye and Vis* 2015;2.
- 24 Yau JWY, Rogers SL, Kawasaki R, et al. Global prevalence and major risk factors of diabetic retinopathy. *Diabetes Care* 2012;35:556–64.
- 25 Jorge R, Costa RA, Calucci D, et al. Intravitreal bevacizumab (Avastin) for persistent new vessels in diabetic retinopathy (IBEPE study). *Retina* 2006;26:1006–13.
- 26 Sinawat S, Rattanapakorn T, Sanguansak T, et al. Intravitreal bevacizumab for proliferative diabetic retinopathy with new dense vitreous hemorrhage after full panretinal photocoagulation. *Eye* 2013;27:1391–6.
- 27 Krick TW, Bressler NM. Recent clinically relevant highlights from the diabetic retinopathy clinical research network. *Curr Opin Ophthalmol* 2018;29:199–205.
- 28 Kim LA, D'Amore PA. A brief history of anti-VEGF for the treatment of ocular angiogenesis. *Am J Pathol* 2012;181:376–9.
- 29 Lin J, Chang JS, Yannuzzi NA, et al. Cost evaluation of early vitrectomy versus Panretinal photocoagulation and intravitreal ranibizumab for proliferative diabetic retinopathy. *Ophthalmology* 2018;125:1393–400.
- 30 Arevalo JF, Maia M, Flynn HW, et al. Tractional retinal detachment following intravitreal bevacizumab (Avastin) in patients with severe proliferative diabetic retinopathy. *Br J Ophthalmol* 2008;92:213–6.
- 31 Nakao S, Ishikawa K, Yoshida S, et al. Altered vascular microenvironment by bevacizumab in diabetic fibrovascular membrane. *Retina* 2013;33:957–63.