

BRIEF REPORT

Open Access



Diffuse myocardial fibrosis is uncommon in people with perinatally acquired human immunodeficiency virus infection

Jason L. Williams¹, Frances Hung², Elizabeth Jenista^{3,4}, Piers Barker⁵, Hrishikesh Chakraborty⁵, Raymond Kim^{6,7}, Andrew W. McCrary¹, Svati H. Shah^{8,9}, Nathan Thielman¹⁰ and Gerald S. Bloomfield^{11,12*}

Abstract

Background Cardiovascular disease (CVD) remains a leading cause of death in people living with HIV. Myocardial fibrosis is well-described in HIV infection acquired in adulthood. We evaluate the burden of fibrosis by cardiac magnetic resonance in people with perinatal HIV infection.

Methods Individuals with perinatally acquired HIV (pnHIV) diagnosed before 10 years-old and on antiretroviral treatment for ≥ 6 months were matched with uninfected controls. Patients with significant cardiometabolic co-morbidities and pregnancy were excluded. Diffuse fibrosis was assessed by cardiac magnetic resonance (CMR) with native T1 mapping for calculation of extracellular volume fraction (ECV). Viability was assessed with late gadolinium enhancement. The normality of fibrosis was assessed using the Komogrov-Smirnov test. Fibrosis between the groups was analyzed using a Mann-Whitney U test, as the data was not normally distributed. Statistical significance was defined as a p-value < 0.05 .

Results Fourteen adults with pnHIV group and 26 controls (71% female and 86% Black race) were assessed. The average (\pm standard deviation) age in the study group was 29 (± 4.3) years-old. All pnHIV had been on ART for decades. Demographic data, CMR functional/volumetric data, and pre-contrast T1 mapping values were similar between groups. Diastolic function was normal in 50% of pnHIV patients and indeterminate in most of the remainder (42%). There was no statistically significant difference in ECV between groups; $p = 0.24$.

Conclusion Perinatally-acquired HIV was not associated with diffuse myocardial fibrosis. Larger prospective studies with serial examinations are needed to determine whether pnHIV patients develop abnormal structure or function more often than unaffected controls.

Keywords Perinatal infection, HIV, Myocardial fibrosis

*Correspondence:
Gerald S. Bloomfield
gerald.bloomfield@duke.edu

Full list of author information is available at the end of the article



© The Author(s) 2024. **Open Access** This article is licensed under a Creative Commons Attribution 4.0 International License, which permits use, sharing, adaptation, distribution and reproduction in any medium or format, as long as you give appropriate credit to the original author(s) and the source, provide a link to the Creative Commons licence, and indicate if changes were made. The images or other third party material in this article are included in the article's Creative Commons licence, unless indicated otherwise in a credit line to the material. If material is not included in the article's Creative Commons licence and your intended use is not permitted by statutory regulation or exceeds the permitted use, you will need to obtain permission directly from the copyright holder. To view a copy of this licence, visit <http://creativecommons.org/licenses/by/4.0/>. The Creative Commons Public Domain Dedication waiver (<http://creativecommons.org/publicdomain/zero/1.0/>) applies to the data made available in this article, unless otherwise stated in a credit line to the data.

Introduction

Despite increased life expectancy with widespread use of antiretroviral therapy (ART), cardiovascular disease (CVD) remains a leading cause of mortality in people living with human immunodeficiency virus (PLWH) [1, 2]. Current data suggests that the burden of CVD is approximately 2-fold higher in PWH compared to the uninfected, and still remains a large, recognized risk in PLWH even when factoring in the pre-ART era into consideration [2]. Higher incidence is also seen in lower income regions, such as areas of sub-Saharan Africa (SSA) with the highest HIV burden, where CVD accounts for >10% of all morbidity and mortality [3]. The pathophysiology for developing CVD is incompletely understood; however, etiologies include modifiable and unmodifiable risk factors, such as chronic disease inflammation, ART-associated dyslipidemia, early atherosclerosis, tobacco use, and inequitable care [2–4]. PLWH also have a greater degree of myocardial steatosis and fibrosis, and cardiovascular imaging has been increasingly used to define characteristics of subclinical CVD [5, 6].

Despite recent advances in knowledge about risk factors and prognostication of CVD in PLWH, there are sparse data from individuals with perinatally acquired HIV (pnHIV). Child death from HIV-associated cardiomyopathy has decreased; however, recent studies have shown both transient and chronic functional and structural changes by echocardiography [7, 8]. Cardiovascular magnetic resonance image (CMR) has emerged as a premier modality for assessment of CVD in PLWH, as it can detect abnormal structural, functional, and tissue characterization parameters better than other imaging modalities [4, 5, 9]. CMR has demonstrated fibrosis in assessment of late gadolinium enhancement (LGE) and mapping techniques in PLWH [4]. An increase in extracellular volume (ECV), a more sensitive marker for diffuse fibrosis, has also been described in this cohort. We are not aware of CMR studies that have focused specifically on adults with pnHIV. With this gap in mind, we sought to examine the myocardial tissue composition by CMR, specifically diffuse fibrosis, in patients with pnHIV.

Methods

We enrolled persons with pnHIV, who were current or former patients at the Duke University Medical Center HIV clinic and included a historical control population for comparison. Inclusion criteria included age at diagnosis of less than 10 years-old with ability to provide consent, and administration of ART for at least ≥ 6 months duration, and ability to provide consent. Exclusion criteria included inability to provide consent, tolerate CMR examination, anaphylaxis to gadolinium contrast, recent medical illness requiring hospitalization in the prior 90 days, pregnancy (confirmed by urine pregnancy

testing at the time of scan), breastfeeding, glomerular filtrate rate <30 mL/min/m², hemodialysis-dependent, and arrhythmia. The study was approved by the institutional review board at Duke University Medical Center, Pro00109701.

All newly enrolled participants underwent echocardiography or prior echocardiogram imaging was reviewed if obtained within 24 months. Study participants were age-matched with historic controls, who had no history of HIV infection or maternal exposure and who had undergone a CMR exam with sufficient LGE and ECV imaging. Enrolled and control group patients had no prior history of coronary artery disease, co-morbid inflammatory disease, chronic use of steroids or anti-inflammatory medication, active cancer, chemotherapy or radiation in the past year, myocardial infarction, moderate-severe valvular disease, congenital heart disease, heart failure, non-ischemic cardiomyopathy, atrial fibrillation, or intracardiac defibrillator/pacemaker placement. Common CMR indications for historical control patients included rule out cardiomyopathy and evaluation of chest pain.

CMR exams were performed on a 3T scanner (Siemens MAGNETOM Vida, Erlangen, Germany) in the Duke Cardiovascular Magnetic Resonance Center. Exams included functional analysis using ECG-gated steady-state free-precession (SSFP) cine imaging. Exams also included T2-weighted imaging for assessment of myocardial edema and native T1 mapping for diffuse fibrosis. Following intravenous administration of Gadolinium-based contrast agent (0.15 mmol/kg; Dotarem, Guerbet) late-gadolinium enhancement (LGE) images were acquired to assess for scar/fibrosis and post-contrast T1 mapping was performed to calculate extracellular volume (ECV).

Post-processing of CMR data was performed using Precession, HeartIT (Durham, NC) for function and volumetric analysis. Myocardial edema was assessed visually on T2-weighted images. T1 maps were quantitatively assessed using the inline color map provided by the scanner manufacturer (Siemens, Erlangen, Germany). Myocardial T1 relaxation time was manually measured from the maps by carefully contouring the endocardial and epicardial borders, excluding epicardial fat and blood pool [10]. LGE was scored for presence, location, and extent of hyperenhancement using the 17-segmental model and a 5-point scale as previously described [11].

The normality of fibrosis was checked using the Kolmogorov-Smirnov test. Fibrosis between the groups was analyzed using a Mann-Whitney U test as the data was not normally distributed. Statistical significance was defined as a p -value <0.05.

Results

Fourteen patients were included in the pnHIV group (Table 1). Twenty-six patients without HIV infection were included as historic controls. Average (\pm standard deviation) age in the PWH group was 29 ± 4.3 years-old and the cohort was 71% female. Most patients were Black race (86%), and not of Hispanic or Latino ethnicity (100%). The majority of patients did not have hypertension, hyperlipidemia, diabetes or a smoking history in both groups. Comparison of demographic data revealed similar average values in age, body mass index, body surface area, systolic blood pressure, low-density lipoprotein, total cholesterol, hematocrit, creatinine and estimated glomerular filtration rate between groups. Those in the pnHIV group had slightly higher average diastolic blood pressure, high-density lipoprotein, and triglycerides. Most individuals in the pnHIV group (92%) reported no limitation of physical activity (i.e., New York Heart Association class 1). Excessive alcohol use or illicit drug use was uncommon.

Echocardiographic data demonstrated normal structure and systolic function by both conventional functional assessment and subclinical myocardial strain analysis. Diastolic function was normal in 50% of the pnHIV group and indeterminate in 42%. Functional and volumetric data were similar between groups. Pre-contrast T1 mapping values were similar between groups. There was no statistically significant difference in ECV between groups; $p=0.24$ (Fig. 1).

Discussion

This is the first study to our knowledge to examine diffuse fibrosis in PLWH on ART, who acquired HIV perinatally. This group is of particular importance to study given three decades of HIV exposure, yet with few traditional CVD risk factors. Using historic controls to compare the prevalence of abnormal myocardial fibrosis, we found no statistically significant difference in ECV fraction between pnHIV group versus those unaffected by HIV.

As a part of CMR analysis in these patients, tissue characterization is performed through myocardial T1 and T2 mapping techniques, ECV calculation, and assessment of LGE by direct visualization. LGE is the gold standard for assessment of non-viable myocardium; however, LGE may not detect diffuse fibrosis due to lack of normal myocardium in extensive disease and limitations of spatial resolution [12]. ECV fraction is a marker of diffuse fibrosis, derived from native T1 values, shortened post-contrast T1 values (following administration of gadolinium-based contrast agents), and hematocrit. ECV provides an estimate of interstitial and extracellular matrix, which increases with ventricular remodeling and collagen deposition in disease states, such as myocarditis.

CMR-based fibrosis in chronic HIV infection is well-established in patients that acquired HIV later in life [4].

Fibrosis in PLWH has important prognostic implications, including development of heart failure and death [13, 14]. Outcome studies in PLWH demonstrated higher prevalence of diffuse myocardial fibrosis by CMR in patients who had cardiac events compared to those that did not during short interval follow-up [14]. There was also statistically significant difference in myocardial edema and native T2 values in patients who had events compared to those who did not [14]. In our study, we found no differences in T1 mapping and ECV fraction between the patients with perinatal HIV from controls. Reasons are likely multifactorial and raises the question whether there are intrinsic differences between treated perinatal HIV infection and infection acquired later in life, as it relates to immune regulation, viral replication, antiretroviral exposures, and other mechanisms [15]. In a cross-sectional CMR-based study in South Africa, prolonged exposure to ART in perinatal infection is thought to be cardioprotective, causing less severe left ventricular remodeling, as evidenced by lower mass-to-volume ratio when compared to uninfected controls. No difference in tissue characterization was seen between groups [16]. Another possibility in our cohort is the low overall burden of fibrosis, which could yield non-significant difference in ECV. In a small prospective cohort study, LGE was seen in a majority of patients with HIV compared to controls; however, the overall volume of LGE was low at 3.4%. The authors suggested that the low extent of fibrosis, may also explain why there was nonsignificant difference in ECV fraction [17].

Our patient population with pnHIV is younger by decades than most published studies of PLWH who have undergone CMR to evaluate for fibrosis. Younger patients may lack traditional modifiable risk factors for early CVD, specifically dyslipidemia. In our study population, the prevalence of chronic metabolic conditions known to place patients at increased risk of CVD, such as obesity, diabetes mellitus, and hypertension, was low [17]. In addition, the majority of these patients had never smoked nor had coronary artery disease or myocardial infarction. When CVD risk factors are absent, adults with PLWH are less likely to have diastolic dysfunction by echocardiogram suggesting an important role of traditional CVD risk factors that may work in tandem with HIV to impair cardiac function [18]. While CVD in PLWH is likely related to viral infection, ART administration, and other co-morbidities, younger patients who have not acquired the compounded modifiable risks may lack CMR-based fibrosis.

Early and sustained exposure to ART is also likely to play a role in mitigating cardiac fibrosis. With pnHIV initiation of ART occurs sooner after infection than if

Table 1 Demographic and clinical characteristics of the pnHIV and control groups

	pnHIV (N= 14)	Control, historic from cardiac MRI lab (N= 26)
Demographic and Clinical Data*		
Age (years)	29.1 [27.7, 31.6]	28.0 [25.0, 31.0]
Female Sex	10 (71.4%)	17 (65.4%)
Race		
Black/African-American	12 (85.7%)	22 (84.6%)
White	2 (14.3%)	3 (11.5%)
Unknown	0 (0%)	1 (3.8%)
BMI (kg/m ²)	30.5 [24.5, 35.7]	30.4 [23.7, 34.5]
BSA (m ²)	1.8 [1.7, 2.0]	1.9 [1.7, 2.1]
Hypertension	1 (7.1%)	3 (11.5%)
Missing	0	0
Dyslipidemia	0 (0%)	1 (3.8%)
Missing	0	2
Diabetes Mellitus	1 (7.1%)	0 (0%)
Missing	0	1
Myocardial Infarction	0 (0%)	0 (0%)
Missing	0	1
NYHA Class		
NYHA Class I	13 (92.9%)	--
NYHA Class II	1 (7.1%)	--
Laboratory Data		
eGFR (mL/min)	114.1 [92.3, 124.7]	93.3 [87.4, 119.3]
Missing	1	3
CD4 count (cells/uL)	632.5 [562.5, 1171.2]	--
Viral load (copies/mL)	0.0 [0.0, 23.0]	--
Missing	3	--
LV Mass Index (g/m ²)	63.3 [54.8, 79.5]	--
Missing	0	--
Relative Wall Thickness (cm)	0.4 [0.3, 0.4]	--
LVIDd (cm)	4.5 [4.3, 4.7]	--
Calculated EF (%)	58.0 [55.0, 60.0]	--
Missing (n)	1	--
E/A Ratio	1.5 [1.4, 1.6]	--
E/E' Ratio	6.6 [6.0, 8.0]	--
Global Longitudinal Strain (%)	-18.1 [-19.2, -17.2]	--
CMR Data		
T1 Pre-Contrast (milliseconds)	1230.1 [1220.1, 1242.9]	1235.4 [1210.4, 1256.0]
Missing	1	0
Extracellular Volume (%)	25.5 [24.1, 27.5]	27.5 [23.7, 28.8]
Missing	1	0
LV End-Diastolic Volume (mL)	139.7 [128.0, 147.0]	127.8 [114.1, 156.0]
Missing	1	0
LV End-Systolic Volume (mL)	58.8 [46.8, 60.8]	49.7 [43.1, 66.2]
Missing	1	0
LV Ejection Fraction (%)	58.4 [58.0, 63.8]	61.3 [58.4, 63.0]
Missing	1	0
LV Cardiac Output (Liters/minute)	5.6 [5.2, 6.0]	5.8 [5.2, 6.3]
Missing	1	0
LV Mass (grams)	96.5 [81.9, 104.7]	102.0 [82.5, 132.7]
Missing	1	0

*All data Median [Q1, Q3] or n(%)

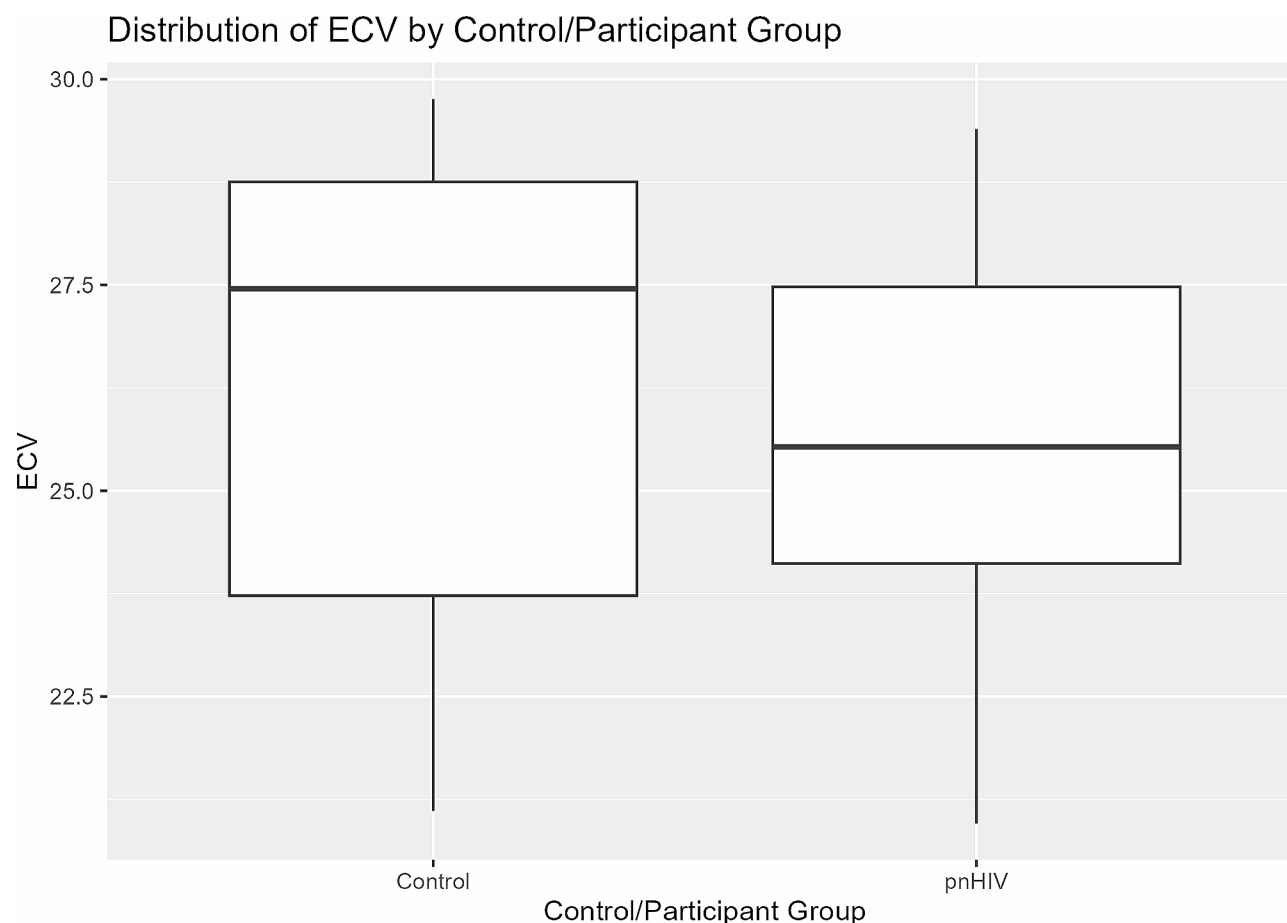


Fig. 1 Extracellular volume in pnHIV and control groups

infection acquired later in life [19, 20]. Longer duration of ART results in less end-organ damage as the result of sustained undetectable viral load [21]. In a prospective study following serial CMR data in treatment naive patients with repeat exam after 9 months on ART, myocardial edema improved as evidenced by a decrease in native T1, T2 values, and ECV fraction [22]. Improvement in tissue composition was associated with a decrease in viral load and CRP, with an increase in CD4 cell count, suggesting that myocardial inflammation and edema are responsive to ART [22]. Improvement in inflammation supports the hypothesis that early initiation of ART in pnHIV improves cardiac tissue characteristics in these patients compared to infection acquired later.

There are several limitations to our study. This was a pilot study in an under-studied population that was limited in sample size. Our study may not have been sufficiently powered to detect difference in ECV, as it was difficult to recruit patients to undergo CMR examination during the COVID-19 epidemic. The patients recruited in our study are also likely to be the most compliant patients. As such, the findings may not be as generalizable to a broader context of PLWH. Our study was also a

cross-sectional design, and did not prospectively follow patients longitudinally with serial CMRs to detect subtle changes in pre-contrast T1, LGE or ECV with time.

Conclusion

No differences were detected in CMR-based markers of cardiac fibrosis among young adults with pnHIV and controls. Future direction should include serial assessment of tissue characterization over time, and compare pnHIV patients to both unaffected controls and patients who acquired infection later in life.

Acknowledgements

The authors would like to thank Dr. David Wendell for his review of the technical aspects of cardiac magnetic resonance acquisition and post-processing for this manuscript.

Author contributions

JLW was a major contributor in the writing and editing of the manuscript. FH contributed to the study design, collection, analysis of the data and creation of the table/figures. EJ contributed to the design and conceptualization of the cardiovascular magnetic resonance technical aspects, image acquisition, and data analysis. PB contributed the editing of the manuscript. HC contributed to the study design, analysis and editing of the manuscript. RK contributed to conceptualization of the cardiovascular magnetic resonance technical aspects, image acquisition, and data analysis. AWM contributed to the conceptualization of the study and significant editing of the manuscript.

SHS contributed to the study design, collection and analysis of the data. NT contributed to the study design and significant editing of the manuscript. GSM contributed to the study design, conceptualization, collection, analysis, writing and editing of the manuscript.

Funding

This study was supported by a grant from the National Heart Lung and Blood Institute (R56HL152803).

Data availability

The datasets used and/or analyzed during the current study are available from the corresponding author on reasonable request.

Declarations

Ethics approval and consent to participate

The study was approved by IRB Pro00109701.

Consent for publication

Not applicable.

Competing interests

The authors declare they have no competing interests.

Authors' information

Not applicable.

Author details

¹Division of Pediatric Cardiology, Duke University Medical Center, Durham, NC, USA

²Department of Biostatistics and Bioinformatics, Duke University School of Medicine, Durham, NC, USA

³Duke Cardiovascular Magnetic Resonance Center, Duke University Medical Center, Durham, NC, USA

⁴Division of Cardiology, Duke University Medical Center, Durham, NC, USA

⁵Duke Clinic Research Institute, Durham, NC, USA

⁶Department of Radiology, Duke University Medical Center, Durham, NC, USA

⁷Duke Clinic Research Institute and Duke University School of Medicine, Durham, NC, USA

⁸Duke Clinic Research Institute and Duke University School of Medicine, Durham, NC, USA

⁹Department of Medicine, Duke University School of Medicine, Durham, NC, USA

¹⁰Division of Infectious Diseases and International Health, Department of Medicine, University Medical Center, Durham, NC, USA

¹¹Department of Medicine, Duke University Medical Center, DUMC Box 3850, 27705 Durham, NC, USA

¹²Duke Clinical Research Institute, and Duke Global Health Institute, Duke University, Durham, NC, USA

Received: 19 September 2023 / Accepted: 22 February 2024

Published online: 04 March 2024

References

- Deeks SG, Lewin SR, Havlir DV. The end of AIDS: HIV infection as a chronic disease. *Lancet*. 2013;382(9903):1525–33.
- Feinstein MJ, Hsue PY, Benjamin LA, Bloomfield GS, Currier JS, Freiberg MS, et al. Characteristics, Prevention, and management of Cardiovascular Disease in people living with HIV: A Scientific Statement from the American Heart Association. *Circulation*. 2019;140(2):e98–e124.
- Shah ASV, Stelzle D, Lee KK, Beck EJ, Alam S, Clifford S, et al. Global Burden of Atherosclerotic Cardiovascular Disease in people living with HIV: systematic review and Meta-analysis. *Circulation*. 2018;138(11):1100–12.
- Hudson JA, Majonga ED, Ferrand RA, Perel P, Alam SR, Shah ASV. Association of HIV infection with Cardiovascular Pathology based on Advanced Cardiovascular Imaging: a systematic review. *JAMA*. 2022;328(10):951–62.
- Thiara DK, Liu CY, Raman F, Mangat S, Purdy JB, Duarte HA, et al. Abnormal myocardial function is related to myocardial steatosis and diffuse myocardial fibrosis in HIV-Infected adults. *J Infect Dis*. 2015;212(10):1544–51.
- Neilan TG, Nguyen KL, Zaha VG, Chew KW, Morrison L, Ntusi NAB, et al. Myocardial steatosis among antiretroviral therapy-treated people with human immunodeficiency virus participating in the REPRIEVE trial. *J Infect Dis*. 2020;222(Suppl 1):63–s9.
- Vallilo NG, Durigon GS, Lianza AC, de Fátima Rodrigues Diniz M, Shiraishi Sawamura KS, Brito CR, et al. Echocardiographic follow-up of perinatally HIV-infected children and adolescents: results from a single-center Retrospective Cohort Study in Brazil. *Pediatr Infect Dis J*. 2020;39(6):526–32.
- Dirajlal-Fargo S, McComsey GA. Cardiometabolic complications in Youth with perinatally acquired HIV in the era of antiretroviral therapy. *Curr HIV/AIDS Rep*. 2021;18(5):424–35.
- Holloway CJ, Ntusi N, Suttie J, Mahmod M, Wainwright E, Clutton G, et al. Comprehensive cardiac magnetic resonance imaging and spectroscopy reveal a high burden of myocardial disease in HIV patients. *Circulation*. 2013;128(8):814–22.
- Messroghli DR, Moon JC, Ferreira VM, Grosse-Wortmann L, He T, Kellman P, et al. Clinical recommendations for cardiovascular magnetic resonance mapping of T1, T2, T2* and extracellular volume: a consensus statement by the Society for Cardiovascular Magnetic Resonance (SCMR) endorsed by the European Association for Cardiovascular Imaging (EACVI). *J Cardiovasc Magn Reson*. 2017;19(1):75.
- Kim RJ, Wu E, Rafael A, Chen EL, Parker MA, Simonetti O, et al. The use of contrast-enhanced magnetic resonance imaging to identify reversible myocardial dysfunction. *N Engl J Med*. 2000;343(20):1445–53.
- Haaf P, Garg P, Messroghli DR, Broadbent DA, Greenwood JP, Plein S. Cardiac T1 mapping and extracellular volume (ECV) in clinical practice: a comprehensive review. *J Cardiovasc Magn Reson*. 2016;18(1):89.
- Chen Y, Gao Y, Zhou Y, Li X, Wang H, Polonsky TS, et al. Human immunodeficiency virus infection and Incident Heart failure: a Meta-analysis of prospective studies. *J Acquir Immune Defic Syndr*. 2021;87(1):741–9.
- de Leuw P, Arendt CT, Haberl AE, Frodinadl D, Kann G, Wolf T, et al. Myocardial fibrosis and inflammation by CMR Predict Cardiovascular Outcome in people living with HIV. *JACC Cardiovasc Imaging*. 2021;14(8):1548–57.
- Hsue PY, Tawakol A. Inflammation and fibrosis in HIV: getting to the heart of the Matter. *Circ Cardiovasc Imaging*. 2016;9(3):e004427.
- Magodoro IM, Guerrero-Chalela CE, Claggett B, Jeremy S, Samuels P, Zar H et al. Left ventricular remodeling and its correlates among adolescents with perinatally acquired HIV in South Africa. *Int J Cardiol*. 2023;131121.
- Luetkens JA, Doerner J, Schwarze-Zander C, Wasmuth JC, Boesecke C, Sprinkart AM, et al. Cardiac magnetic resonance reveals signs of subclinical myocardial inflammation in asymptomatic HIV-Infected patients. *Circ Cardiovasc Imaging*. 2016;9(3):e004091.
- Woldu B, Temu TM, Kirui N, Christopher B, Ndege S, Post WS et al. Diastolic dysfunction in people with HIV without known cardiovascular risk factors in Western Kenya. *Open Heart*. 2022;9(1).
- Payne H, Chan MK, Watters SA, Otwayombe K, Hsiao NY, Babiker A, et al. Early ART-initiation and longer ART duration reduces HIV-1 proviral DNA levels in children from the CHER trial. *AIDS Res Ther*. 2021;18(1):63.
- Flynn PM, Abrams EJ. Growing up with perinatal HIV. *Aids*. 2019;33(4):597–603.
- Lundgren JD, Babiker AG, Gordin F, Emery S, Grund B, Sharma S, et al. Initiation of antiretroviral therapy in early asymptomatic HIV infection. *N Engl J Med*. 2015;373(9):795–807.
- Robbertse PS, Doubell AF, Lombard CJ, Talle MA, Herbst PG. Evolution of myocardial oedema and fibrosis in HIV infected persons after the initiation of antiretroviral therapy: a prospective cardiovascular magnetic resonance study. *J Cardiovasc Magn Reson*. 2022;24(1):72.

Publisher's Note

Springer Nature remains neutral with regard to jurisdictional claims in published maps and institutional affiliations.