

CASE REPORT

Open Access



Long-term successful management of recurrent episodes of nontuberculous mycobacterial infection in an apparently healthy Chinese woman

Angelo Roberto Raccagni^{1*}, Giovanni Mori¹, Valeria Poletti de Chaurand², Raffaele Dell'Acqua³, Daniela Maria Cirillo^{1,2}, Chiara Oltolini³, Benedetta Mazzi⁴, Francesco Scmazzone⁵, Antonella Castagna^{1,3} and Monica Guffanti³

Abstract

Background Disseminated non-tuberculous mycobacteria (dNTM) infections are mostly reported among individuals with an underlying congenital or acquired immunodeficiency or receiving immunosuppressive treatment, but are rarely documented in otherwise healthy subjects.

Case presentation We describe a case of recurrent disseminated mycobacterial infection in an apparently immunocompetent Chinese woman. *Mycobacterium szulgai* and *Mycobacterium avium-complex* were identified in distinct episodes. Long-term antimycobacterial therapy was administered given the occurrence of recurrent events when off-treatment. Successful management over more than 10 years and immunologic data are reported.

Conclusions This case-report highlights that dNTM should be suspected also among apparently immunocompetent hosts and that thorough assessment of underlying immune-impairments is helpful to define patients' management. Long-term antimycobacterial therapy and close monitoring is required to grant successful outcomes in case of recurrent dNTM infections.

Keywords Nontuberculous mycobacteria, Antimycobacterial therapy, IL-12/IFN- γ pathway

Background

Disseminated non-tuberculous mycobacteria (dNTM) infections are mostly reported among individuals with an underlying congenital or acquired immunodeficiency or receiving immunosuppressive treatment, but are rarely documented in otherwise healthy subjects [1]. Diagnosis may initially prove challenging due to non-specific symptoms, which may mimic oncologic disease. [2, 3] The recognition of underlying immune defects plays an important role in the subsequent management of dNTM infections.

Different primary and acquired immunodeficiencies determine an increased susceptibility to mycobacterial

*Correspondence:

Angelo Roberto Raccagni
raccagni.angelo@hsr.it

¹Vita-Salute San Raffaele University, Via Stamira D'Ancona 20, Milano 20127, Italy

²Emerging Bacterial Pathogens Unit, Division of Immunology, Transplantation and Infectious Diseases, IRCCS San Raffaele Scientific Institute, Milan, Italy

³Unit of Infectious Diseases, IRCCS San Raffaele Scientific Institute, Milan, Italy

⁴Immunogenetics Laboratory, Department of Immunohematology & Blood Transfusion, IRCCS San Raffaele Scientific Institute, Milan, Italy

⁵Department of Neuroradiology, IRCCS San Raffaele Scientific Institute, Milan, Italy



© The Author(s) 2024. **Open Access** This article is licensed under a Creative Commons Attribution-NonCommercial-NoDerivatives 4.0 International License, which permits any non-commercial use, sharing, distribution and reproduction in any medium or format, as long as you give appropriate credit to the original author(s) and the source, provide a link to the Creative Commons licence, and indicate if you modified the licensed material. You do not have permission under this licence to share adapted material derived from this article or parts of it. The images or other third party material in this article are included in the article's Creative Commons licence, unless indicated otherwise in a credit line to the material. If material is not included in the article's Creative Commons licence and your intended use is not permitted by statutory regulation or exceeds the permitted use, you will need to obtain permission directly from the copyright holder. To view a copy of this licence, visit <http://creativecommons.org/licenses/by-nc-nd/4.0/>.

infections. [4, 5] Primary immunodeficiencies, linked to genetic defects, are referred as mendelian susceptibility to mycobacterial disease. [4, 5] Acquired immunodeficiency sustained by anti-interferon- γ autoantibodies (anti-IFN- γ Abs), as well as immunosuppressive treatment, impaired immune function due to an underlying malignancy or late-stage HIV infection, are also predisposing factors to mycobacterial infections. [1, 5, 6].

For appropriate dNTM management, species identification and antimycobacterial susceptibility testing (AST) are important, as long-term therapy is required due to persistent or recurrence of infection, despite initially intensive treatment. [7, 8].

Furthermore, considering long-term therapy, drug toxicities and adherence are critical in the management of the disease. [8, 9].

In this report, we describe the case of an apparently immunocompetent Chinese woman with recurrent dNTM; follow-up over more than 10 years is reported.

Case presentation

In December 2011, a 51-year-old Chinese woman presented to the Infectious Diseases Unit, IRCCS San Raffaele Scientific Institute, Milan, Italy, with multiple lymphadenopathies, lung and skeletal involvement, fever, hemoptysis and cachexia.

A year earlier, the patient was successfully treated with levofloxacin for fever, diffuse osteoarticular pain, asthenia, and weight loss in state of anemia (Hb=10.5 g/dl), leukocytosis (WBC=18.9 $\times 10^9$ /l) and alteration of C-reactive protein (CRP=26.4 mg/l, normal range=2–6). Microbiological tests (blood cultures, detection of mycobacteria in stool, urine, sputum and blood) and tuberculin skin test (TST) resulted negative. In the next months,

due to recurrence of the clinical picture, worsened by multiple lymphonodal, lung (right paramediastinal mass and nodules) and skeletal involvement (lytic lesions of left ribs and pelvis) documented by computerized tomography (CT) and positron emission tomography (PET), the patient was referred to the Oncology Department where an hypothesis of hematological malignancy was formulated, which was not confirmed by diagnostic investigations (lung, bone, right axillary lymphonodal and bone marrow biopsy resulted inconclusive for lymphoproliferative disorder, and suggestive for histiocytic proliferative process in presence of granulomatous lymphadenitis).

During the hospitalization, an episode of varicella-zoster virus (VZV) reactivation was observed. Combined antalgic therapy (anti-inflammatory, opioid and GABA analogue) was introduced due to bone pain and neuropathy. Total body CT showed progression of lymphonodal, lung and skeletal involvement (Fig. 1A).

A lateral-cervical lymphonodal biopsy was performed with histological examination indicative for an atypical lymphoproliferative process with associated microgranulomas and rare bacilliform structures to Truant staining. Blood cultures and culture of the lateral-cervical lymph node grew NTM identified as *Mycobacterium szulgai* by molecular method (16 S rRNA). AST showed susceptibility to clarithromycin (CAM), rifabutin (RFB), rifampicin (RIF), ethambutol (EMB), moxifloxacin (MXF), amikacin (AMK), linezolid (LZD) and resistance to doxycycline (DOXI) and cotrimoxazole (SXT).

Anemia (9 g/dl), leukocytosis (19.3 $\times 10^9$ /l, with eosinophilia (0.8 $\times 10^9$ /l), increase in CRP (126 mg/l) and IgE (1384 UI/ml, normal range=0–100) were recorded. QuantiFERON-TB Gold In-tube (QFT-GIT) test resulted indeterminate, and analysis of lymphocytic subpopulations

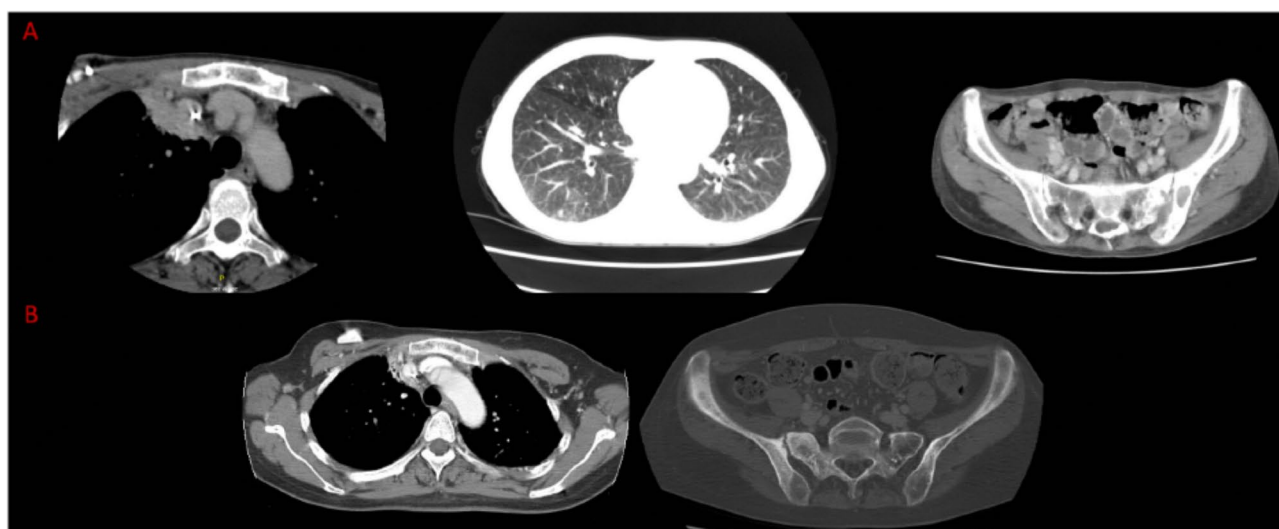


Fig. 1 (A) CT scan showing involvement of: right paramediastinal mass (left), lung nodules (middle), lytic lesions of pelvis (right). (B) CT scan showing improvement of: right paramediastinal mass (left), lytic lesions of pelvis (right)

showed a CD4/CD8 ratio=0.74 (CD4⁺ 428 cell/mm³-25%, CD8⁺ 582 cell/mm³-34%).

Intravenous (iv) antimycobacterial therapy (RIF, EMB, isoniazid [INH], azithromycin [AZM]) was introduced, with a switch to oral (po) administration after 4 weeks, obtaining gradual normalization of body temperature and partial improvement of the clinical conditions.

Due to resumption of pyrexia during oral treatment and given signs of malabsorption, antimycobacterial therapy was re-switched to iv and a venous central device (port-a-cath) was implanted, planning a long-term treatment in the day-hospital service. Electrolyte supplementation was introduced because of severe hypokalemia probably related to renal tubulopathy.

After six months of iv therapy, a partial reduction in the extent of the disease was documented by total body CT, associated with overall clinical improvement with initial weight gain; therapy was therefore switch to po administration.

In relation to the onset of progressively worsening distal polyneuropathy, isoniazid was discontinued after 11 months. Quantitative somatosensory test documented significant increase in the perceptual thresholds for thermal and vibratory stimuli in the lower limbs, compatible with dysfunction of the fibers of the A-delta, C and A-beta contingents.

Disease restaging by CT total body performed after 7 months of po therapy confirmed radiological improvement (Fig. 1B).

AZM was substituted with MXF due to itching and subsequently antimycobacterial therapy was stopped after 16 months due to persistence of symptom.

Antalgic therapy was reduced until discontinuation for bone pain resolution, carrying on GABA analogue due to peripheral neuropathy. Laboratory test showed

resolution of anemia, progressive CRP reduction and persistence of mild eosinophilia and high IgE.

Subsequent follow up by CT total body, laboratory test and clinical examination confirmed progressive improvement of the pulmonary radiological picture, lymphadenopathies reduction, partial lytic bone lesions repair, and weight gain.

At 16 months of follow up thoracic pain and VZV reactivation with anemia and CRP increase was observed. CT and MRI revealed multiple lymphadenopathies, liver, spleen and skeletal involvement (bilateral ribs and dorso-lumbar spine) (Fig. 2A). Antalgic therapy (anti-inflammatory and opioid) was reintroduced and CAMP-C35 was prescribed. Disseminated *Mycobacterium avium-complex* (MAC) infection was documented by means of vertebral biopsy. Antimycobacterial therapy (MXF, EMB, RIF) was reintroduced and subsequently modified with AZM instead of MXF based on antibiogram data (R-LZD, R-MXF, S-CAM). Despite treatment, clinical conditions worsened (fever, sweats, uncontrolled pain distributed to the spine, ribs and sternum, left cervical-occipital-mastoid region, radiating to the ipsilateral skull cap and hemiface) with persistence of anemia, CRP and IgE increase with eosinophilia and progression of skeletal involvement, as shown by brain MRI (pachymeningeal thickening with enhancement on the left parietal site at and in contact with an overlying focal lesion of the cranial theca) and spine MRI (progression of known lesions and new pathological alterations affecting cervical-dorsal-lumbar spine) (Fig. 2B). Lumbar puncture excluded meningeal involvement and was negative for mycobacteria.

In order to increase drugs bioavailability, antimycobacterial therapy was switched to iv and antalgic treatment was enhanced.

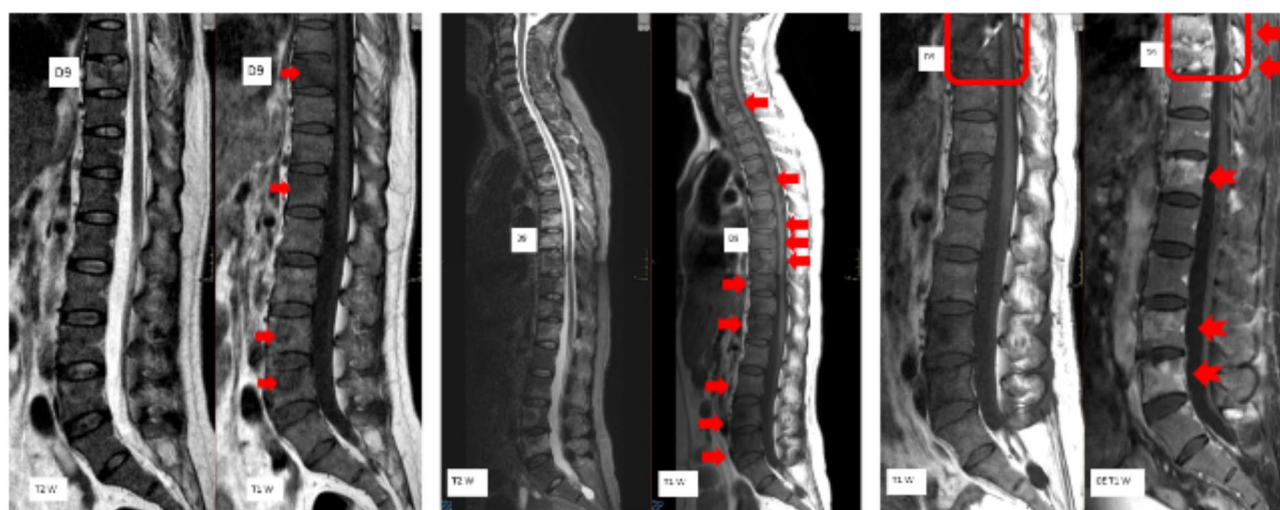


Fig. 2 (A) MRI showing spinal involvement. (B) MRI showing progression of spinal involvement. (C) MRI showing skeletal disease progression in presence of paravertebral pathologic tissue surfacing in the epidural endorachis at D8-D9

After further three months, restaging of the disease was planned due to non-response to treatment. CT and MRI showed skeletal disease progression in presence of paravertebral pathologic tissue surfacing in the epidural endorachis D8-D9 site (Fig. 2C).

Further antimycobacterial treatment strengthening was necessary with the association of AMK and clofazimine (CLO).

Due to progressive hearing loss during treatment with AZM and the start of amikacin, audiometry was planned with subsequent follow up. In addition, a periodic visual inspection was carried out during treatment with EMB.

After 4 months of five-drugs combination therapy, a partial clinical and radiological response was observed by CT. Antimycobacterial therapy was simplified by discontinuing AMK and switching to the remaining drugs, with AZM administered 5 out of 7 days. Antalgic therapy was progressively reduced. A non-significant change in audiometry was observed during treatment with amikacin.

MRI performed after two months of simplified treatment confirmed radiological improvement (Fig. 3A), together with significant bone pain reduction and CRP normalization, partial hemoglobin recovery with fluctuating IgE and eosinophil values. Antimycobacterial therapy was further simplified with CLO withdrawal (toxicity: bronze skin coloring) and AZM frequency reduction (500 mg 3 times a week). Opioid therapy was discontinued.

Periodic evaluations were performed during simplified treatment. A progressive clinical improvement was observed further confirmed by CRP normalization, anemia resolution, despite persistence alterations of IgE and eosinophils.

Follow up MRI was performed 14 months after simplification and confirmed further radiological improvement with persistence of D8-D9 enhancement of reduced

intensity (Fig. 3B). PET showed resolution of skeletal involvement, but tracer accumulation in mediastinal lymph nodes and right upper lung lobe. Chest CT documented the appearance of areas of parenchymal consolidation with ground-glass thickening and slight increase in mediastinal lymph nodes was documented. No further investigations were planned considering the patient's asymptomatic status, with negative CRP.

An MRI follow up was performed 1 year after the previous one, with stable findings (Fig. 3C).

Antimycobacterial therapy was discontinued after 44 months based on clinical and radiological improvement with persistently negative CRP, despite the persistence of mild eosinophilia and elevated IgE.

Two months after therapy withdrawal, an episode of probably bacterial pneumonia was documented. PET showed a marked increase of tracer accumulation in mediastinal lymph nodes and right lung. Oral antimycobacterial therapy (AZM, EMB, RIF) was reintroduced to cover for a mycobacteria reactivation. No NTM were grown on bronchoalveolar lavage, sputum, blood, stool and urines.

Follow up PET and CT scans showed favorable lymph nodal and lung findings without skeletal involvement. Antimycobacterial therapy was then discontinued after 8 months.

A good clinical condition with CRP negative was observed during therapy interruption. Due to the persistence of fluctuating IgE and eosinophils values, parasitological screening was performed with positive serology for *Toxocara canis*. No changes in IgE and eosinophils values were observed despite treatment with albendazole. Following audiometric monitoring, hearing aids were prescribed for worsening hearing loss.

After approximately 15 months of therapy interruption, lymphadenopathies of the neck, diffuse bone pain,

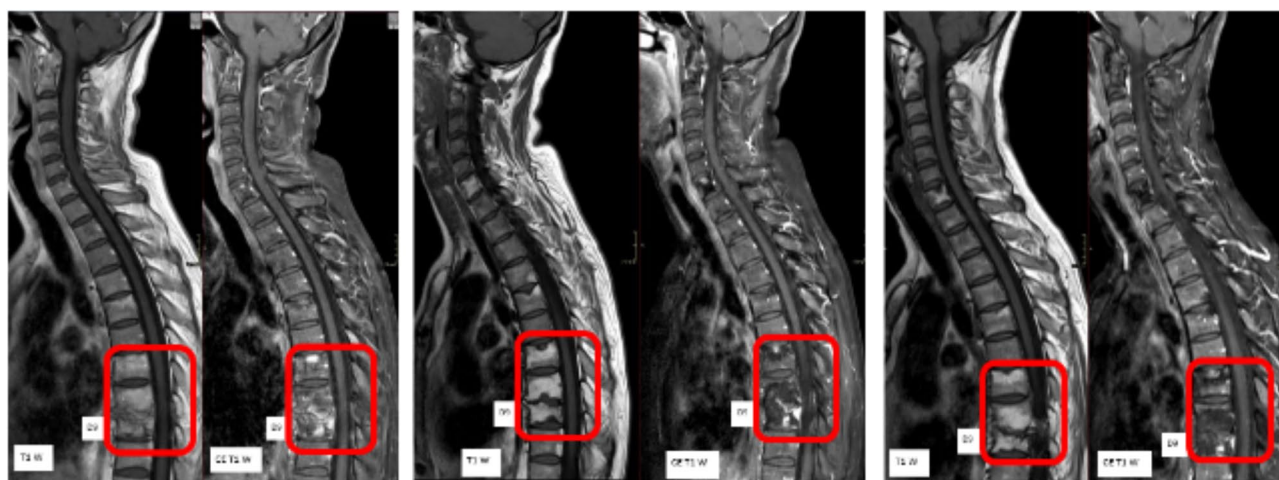


Fig. 3 (A) MRI showing improvement of spinal lesions. (B) MRI showing further improvement of lesions with persistence of D8-D9 enhancement of reduced intensity. (C) MRI showing stable findings

asthenia and weight loss with mild reduction of hemoglobin, CRP and IgE increase were documented. The patient started autonomously antimycobacterial

therapy before seeking medical assistance due to difficulties associated with the COVID pandemic, reporting a decrease of the lymphadenopathy. CT scan, MRI and PET showed lymph nodal, splenic and skeletal, particularly vertebral, involvement (Fig. 4).

In order to diagnose dNTM relapse versus reinfection, antimycobacterial therapy was discontinued. A bone marrow aspiration and a biopsy of the right lateral cervical lymph node were performed; sputum, blood, stool, and urine samples were collected for detection of mycobacteria.

Antimycobacterial therapy (EMB, RIF, AZM and AMK iv; CLO po) was further reintroduced for suspected dNTM relapse/reinfection 17 months after last discontinuation. Because of spinal involvement, CAMP-C35 and Philadelphia collar were prescribed. No NTM were isolated probably due to previous therapy intake. Chronic granulomatous non necrotizing lymphadenitis was observed on lymph node biopsy.

After treatment reintroduction, clinical improvement with recovery of Hb values and negative CRP was documented. Anti-inflammatory was progressively discontinued and antimycobacterial therapy was switched po with posology reduction of AMK and AZM (both 3 times a week), and interruption of AMK after another 3 months in relation to the radiological response shown by PET and MRI (Fig. 5A). No further indication was given for the use of orthopedic devices. During antimycobacterial therapy, a follow up PET was performed after 19 months after the previous one with stable disease (Fig. 5B).

To date, simplified therapy (CLO interruption after 28 months) is ongoing given the recorded good clinical and radiological response. Considering the recurrent episodes of dNTM, HLA molecular typing was performed and HLA-DRB1 *04:05, *15:02 and HLA-DQB1 *04:01, *05:01 were identified (Histo Spot® SSO kits – BAG Diagnostics; Olerup SSP® kits – CareDx).

With reference to the indeterminate QFT-GIT test performed in both the active and remission phases of the disease, the cytokines were quantified on plasma-EDTA by means of Multiplex immunoassays (Bio-Rad) based on Luminex technology (Bio-Plex Pro™ Human Cytokine 27-plex). The analysis revealed that different biomarkers were out of inferior range (among them: IL-1ra, IL-2, IL-5, IL-10, IL-12(p70), IL-15) and recombinant human IFN-γ was barely detectable (Table 1). Summary of radiologic and microbiological investigations and of antimycobacterial therapy is presented in Tables 2 and 3.

Trends of blood parameters are represented in Fig. 6.

Discussion and conclusions

This case describes an apparently healthy subject with recurrent episodes of disseminated mycobacterial infection with isolation of *M. szulgai* and *M. avium* complex in separate events.

Concomitantly to dNTM infection, VZV reactivation was documented twice and *Toxocara canis* infection was documented by serology. Negative TST and several indeterminate QFT-GIT tests were obtained, with underlying CD4⁺ lymphocytes reduction (CD4⁺/CD8⁺<1.0) and persistent IgE and eosinophils elevation, with no complete normalization in the disease remission phase and following toxocariasis treatment. CRP, WBC and Hb were the only markers of the disease.

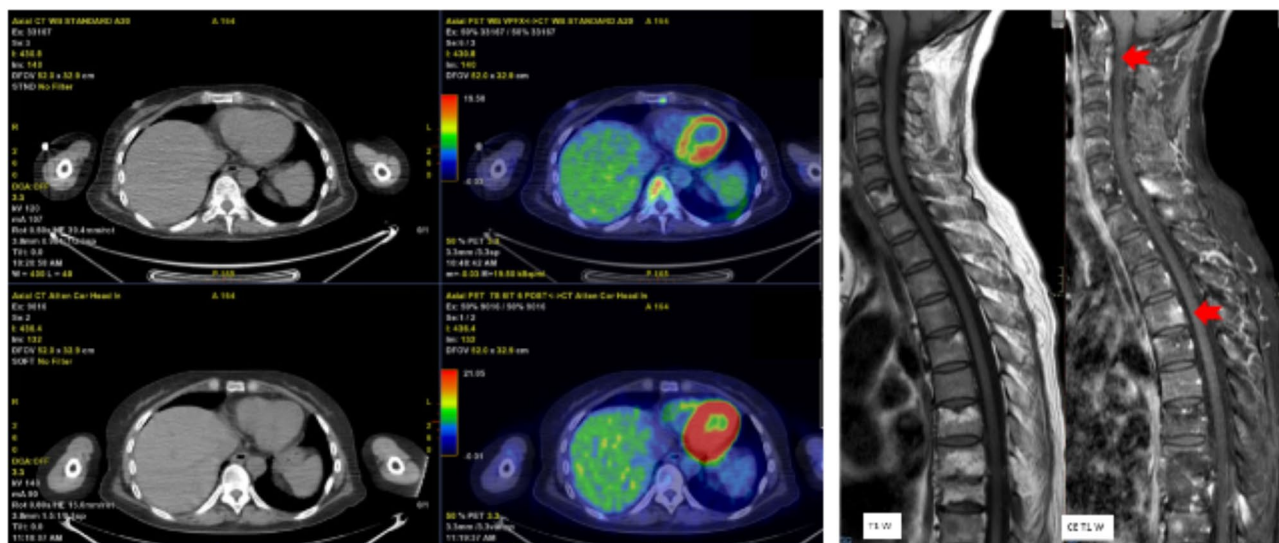


Fig. 4 MRI and PET scan showing splenic and skeletal involvement

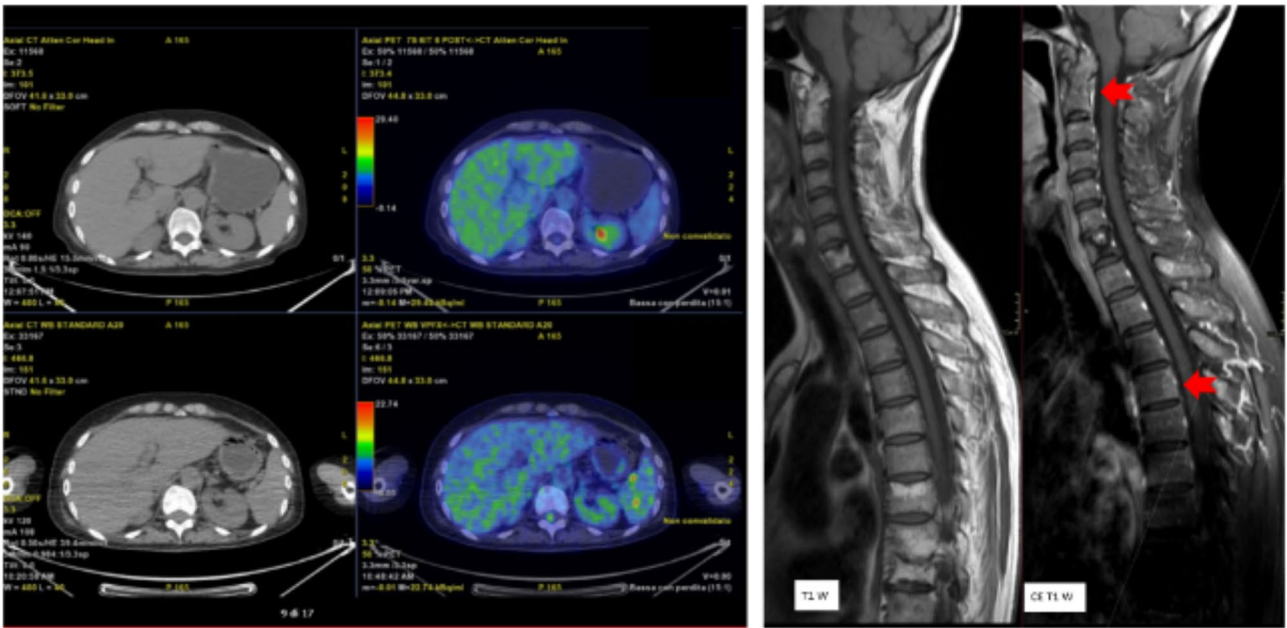


Fig. 5 MRI and PET scan showing favorable disease response

Table 1 Cytokines quantification on plasma-EDTA by means of Bio-plex Pro™ Human Cytokine 27-plex with Multiplex immunoassays (Bio-Rad)

Biomarker (OD Value)	Observed concentration (p/mL)
Hu IL-1b (39)	0,42
Hu IL-1ra (25)	OR<
Hu IL-2 (38)	OR<
Hu IL-4 (52)	0,53
Hu IL-5 (33)	OR<
Hu IL-6 (19)	0,79
Hu IL-9 (77)	109,74
Hu IL-10 (56)	OR<
Hu IL-12(p70) (75)	OR<
Hu IL-13 (51)	0,37
Hu GM-CSF (34)	OR<
Hu IFN-g (21)	0,09*
Hu MIP-1a (55)	0,71
Hu TNF-a (36)	21,7

Abbreviations OOR: out of the inferior range. *: observed concentration lower than expected

Regarding the pathogenesis of mycobacterial infection, the IL-12/IFN- γ pathway and T helper 1 lymphocytes response play a key role in immune defense against mycobacteria, while polarization to T helper 2 activity is associated with poor clinical outcome after treatment [6, 10]. Cytokines dysregulation may impair the formation of granulomas required to encompass mycobacteria, which is usually mediated by the IL-12/IFN- γ pathway, and this defect has been associated with predisposition to persistent NTM infections. [6, 10, 11]

The presence of neutralizing anti-IFN- γ Abs in apparently healthy subjects of Asian origin, who carry a

HLADRB1-DQB1 restricted allelic polymorphism, is a cause of susceptibility to dNTM and co-infections (e.g., VZV reactivation, Salmonella spp.), as described in literature. [11–13]

In our case, the low levels of IFN- γ recorded could be due to the low range of IL-12(p70), that usually contributes to production of IFN- γ by T cells and NK cells, or to the presence of a plasma factor interfering with IFN response, such as neutralizing anti-IFN- γ Abs [14].

Furthermore, an immunosuppressive role is related to IL-10 produced at high levels by monocytes and T cells in MAC infection, but in our case IL-10 was suppressed and consequently not thought to be the cause of IL-12 inhibition [14].

Indeed, in our patient the indeterminate QFT-GIT test reflects a low level of IFN- γ , suggesting the presence of neutralizing anti-IFN- γ Abs, as described by Wu U.I et al. in a previously healthy patient with dNTM infection [15].

With reference to HLA class II, allelic polymorphism HLA-DRB1*16:02 and HLA-DQB1*05:02 has been described in association with anti-IFN- γ Abs in adults with dNTM infections and reactivation of latent VZV infection. [16, 17] In our patient respectively same HLA-DR2 broad antigen and same HLA-DQ5 split antigen were detected.

Antimycobacterial treatment in dNTM infections is challenging since it must take into account the different pathogenic characteristics of mycobacteria species and sensitivity to antimicrobial drugs, potential drug toxicities and adherence issues related to multidrug combination therapy. [8, 9, 13].

Table 2 Summary of radiologic and microbiologic investigations over 10 years of follow-up

Date	Event	Radiology ^Δ	Microbiology
2011	Disseminated <i>Mycobacterium szulgai</i>	CT/MRI/PET: lymph nodes, skeletal and lung involvement	Latero-cervical lymph node biopsy and blood cultures: <i>Mycobacterium szulgai</i> (S-RIF, S-EMB, S-MXF, S-CAM, S-AMK, S-LZD, R-DOXI, R-SXT)
2014	Disseminated MAC	CT/MRI: lymph nodes, skeletal, lung, liver and spleen involvement CT/MRI (+ 7 months): worsening of vertebral lesions	Vertebral biopsy: <i>Mycobacterium avium complex</i> (R-LZD, R-MXF, S-CAM)
2018	Suspected relapse of dNTM	CT/PET: recurrence of thoracic lymphadenopathies	No documented NTM on bronchoalveolar lavage, sputum, blood, stool and urines
2020	Suspected relapse/recurrence of dNTM	CT/MRI/PET: lymph nodes, spleen and skeletal involvement	No documented NTM on bone marrow aspiration, latero-cervical lymph node biopsy, sputum, blood, stool and urines

Abbreviations MAC: *mycobacterium avium complex*; RIF: rifampicin; EMB: ethambutol; MXF: moxifloxacin; CAM: clarithromycin; AMK: amikacin; LZD: linezolid; DOXI: doxycycline; SXT: trimethoprim/sulfamethoxazole; R: resistant; S: susceptible; dNTM: disseminated nontuberculous mycobacteria; CT: computer tomography; MRI: magnetic resonance imaging; PET: positron emission tomography

Table 3 Summary of antimycobacterial therapy over more than 10 years of follow-up

Date	Event	Antimycobacterial therapy	Duration
2011	Disseminated <i>Mycobacterium szulgai</i>	INH, RIF, EMB and AZM	16 Months
	<i>Mycobacterium</i> isolation	RIF, EMB and AZM	11 Months
	INH toxicity	RIF, EMB and MXF	4 Months
	Suspected AZM intolerance		1 Months
2014	Disseminated MAC	RIF, EMB and MXF	44 Months
	<i>Mycobacterium</i> isolation	RIF, EMB and AZM	2 Months
	Antibiogram available	RIF, EMB, AZM, AMK and CLO	5 Months
	Vertebral lesions worsening	RIF, EMB, AZM and CLO	5 Months
	Vertebral lesions improvement	RIF, EMB, AZM	3 Months
	Simplified treatment		29 Months
2018	Suspected relapse/reinfection of dNTM	RIF, EMB and AZM	7 Months
	Thoracic lymphadenopathies/pneumonia		7 Months
2020	Suspected relapse/reinfection of dNTM	RIF, EMB, AZM (discontinuous)	40 Months
	Patient's decision	RIF, EMB, AZM, AMK and CLO	2 Weeks
	Lymphadenopathies/splenic and skeletal lesions recurrence	RIF, EMB, AZM and CLO	5 Months
	Lymphadenopathies/splenic and skeletal lesions improvement	RIF, EMB, AZM	23 Months
			10 Months (ongoing)

Abbreviations INH: isoniazid; RIF: rifampicin; EMB: ethambutol; AZM: azithromycin; MXF: moxifloxacin; AMK: amikacin; CLO: clofazimine; MAC: *mycobacterium avium complex*; dNTM: disseminated nontuberculous mycobacteria

Toxicities. peripheral polyneuropathy (INH); sensorineural hearing loss (AMK, AZM); skin hyperpigmentation (CLO); suspected intolerance (AZM, MXF)

Regarding dNTM infections, international guidelines do not embrace high-level recommendation concerning the duration of therapy and the treatment simplification in view of the lack of randomized clinical trials due both to pathogen and host heterogeneity and to infrequently of disseminated disease [18–20].

In our case, although antimycobacterial therapy was driven by ATS/IDSA guidelines, it was necessary to switch to iv administration for a long period due to poor general condition and multidrug combination therapy, up to five drugs, was started due to clinical and radiological deterioration.

Duration of therapy and simplification schemes were guided by clinical and radiological evolution with careful monitoring of toxicities. Peripheral neuropathy, sensorineural hearing loss, and skin hyperpigmentation were observed in our patient.

Careful follow up during therapy discontinuation is required, as evidenced in our case where recurrent

mycobacterial infections occurred even after a long period of therapy interruption. A short follow up, e.g. 6 months, as defined in some reports, would have allowed our patient to be classified as cured [12].

In case of recurrent episodes, in order to set up the new antimycobacterial therapy scheme, it is important to carry out diagnostic investigations to differentiate a relapse rather than a new infection.

In our case, in conjunction with the last two recurrent episodes, the combined antimycobacterial therapy was chosen based on the clinical and radiological picture, as it was not possible to differentiate a relapse from a new infection, despite diagnostic investigations.

A critical issue is the decision to interrupt the antimycobacterial therapy after three recurrent episodes, which occurred after long periods of remission in the absence of therapy. Currently, a strategy of simplification rather than discontinuation has been chosen to account for the underlying immunological disorder.

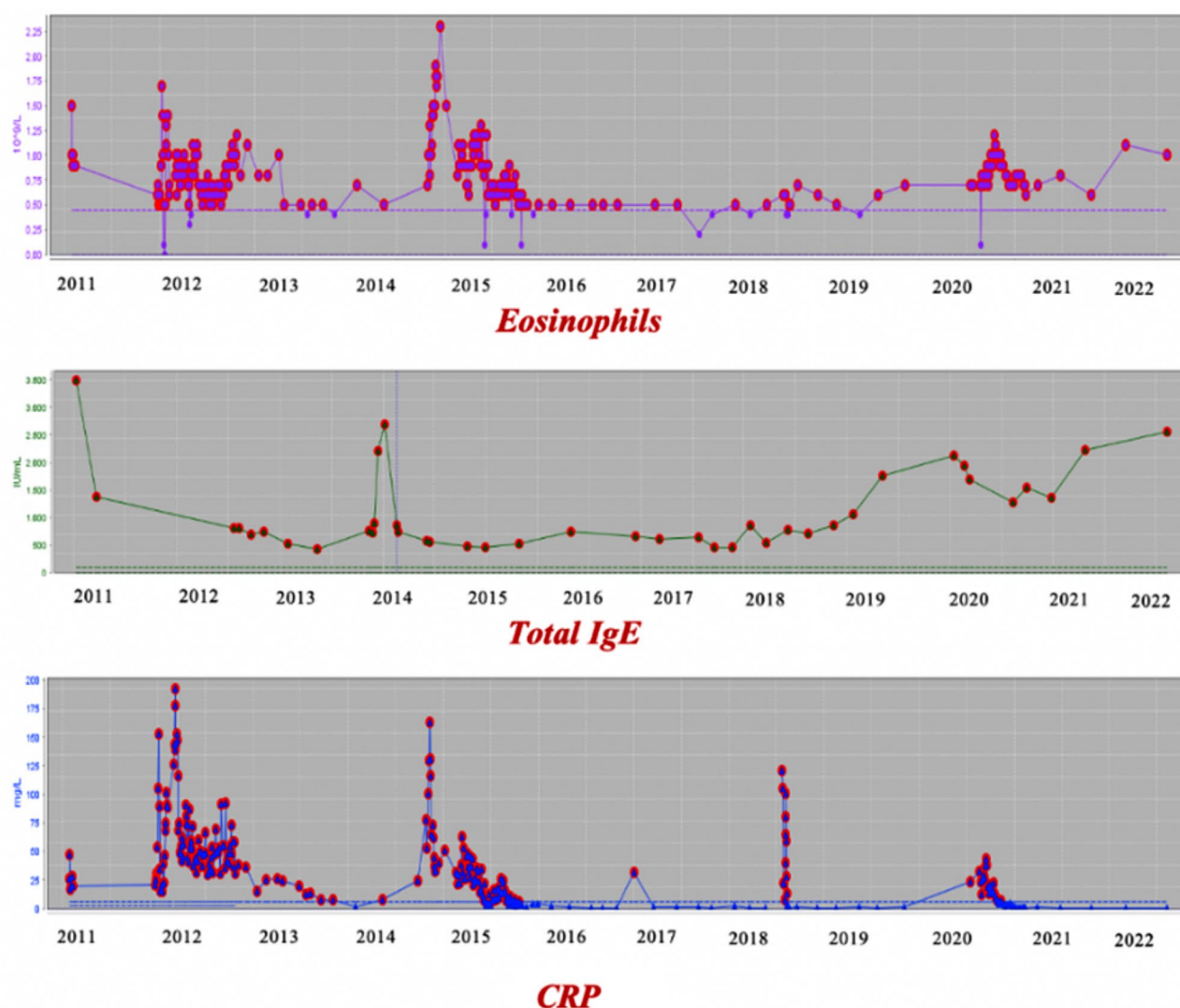


Fig. 6 Eosinophils, total IgE and CRP levels over follow-up

In summary, our case describes an Asian women with recurrent dNTM during therapy interruption, in whom the low levels of IFN- γ with indeterminate QFT-GIT, the reduction of CD4⁺ lymphocytes and the persistence of biomarkers of T helper 2 polarization (IgE/eosinophils), corroborate the idea of an underlying immune-impairment, sustained by neutralizing anti-IFN- γ Abs.

The demonstration of an inadequate immune response accounts for the recurrence of infection on off-therapy and suggests the need to maintain clinical surveillance and long-term antimycobacterial treatment, as in our case followed over more than 10 years.

This case-report highlights that dNTM should be suspected also among apparently immunocompetent hosts and that thorough assessment of underlying immune-impairments is helpful to define patients' management. Long-term antimycobacterial therapy and close

monitoring is required to grant successful outcomes in case of recurrent dNTM infections.

Abbreviations

dNTM	Disseminated non-tuberculous mycobacteria
anti-IFN- γ Abs	Anti-interferon- γ autoantibodies
AST	Antimycobacterial susceptibility testing
Hb	Hemoglobin
WBC	White blood cells
CRP	C-reactive protein
TST	Tuberculin skin test
CT	Computerized tomography
PET	Positron emission tomography
VZV	Varicella-zoster virus
CAM	Clarithromycin
RFB	Rifabutin
RIF	Rifampicin
EMB	Ethambutol
MXF	Moxifloxacin
AMK	Amikacin
LZD	Linezolid
DOXI	Doxycycline
SXT	Cotrimoxazole

QFT-GIT	QuantiFERON-TB Gold In-tube
INH	Isoniazid
AZM	Azithromycin
MAC	Mycobacterium avium-complex
MRI	Magnetic resonance imaging
CLO	Clofazimine

Acknowledgements

The authors acknowledge all healthcare providers of the Infectious Diseases, Microbiology and Emerging Bacterial Pathogens Unit of San Raffaele Scientific Institute.

Author contributions

M.G. is the referring physician of the patient and contributed to the writing of the article. A.R.R. contributed to the writing of the article. A.C. coordinated clinical activities. G.M. reviewed the article. V.P.d.C. and D.M.C. contributed to microbiologic and immunologic analyses and results interpretation. B.M. contributed to immunologic analyses and results interpretations. C.O. and R.D'A. reviewed the article. F.S. contributed to imaging interpretation. All authors read and approved the final manuscript.

Funding

No funding to disclose.

Data availability

No datasets were generated or analysed during the current study.

Declarations

Ethics approval and consent to participate

Informed consent was obtained by the included patient to be included in this study.

Consent for publication

was obtained by the included patient.

Competing interests

The authors declare no competing interests.

Received: 13 February 2024 / Accepted: 29 July 2024

Published online: 03 August 2024

References

- Henkle E, Winthrop K. Nontuberculous Mycobacteria Infections in immunosuppressed hosts. *Clin Chest Med*. 2015 March;36(1):91–9.
- Browne SK, Burbelo PD, Chetchotisakd P, Suputtamongkol Y, Kiertiburanakul S, Shaw PA, Kirk JL, Jutivorakool K, Zaman R, Ding L, Hsu AP, Patel SY, Olivier KN, Lulitanond V, Moosikapun P, Anunnatsiri S, Angkasekwinai N, Sathapatayavongs B, Hsueh PR, Shieh CC, Brown MR, Thongnoppakhun W, Claypool R, Sampaio EP, Thepthai C, Waywa D, Dacombe C, Reizes Y, Zelazny AM, Saleeb P, Rosen LB, Mo A, Iadarola M, Holland SM. Adult-onset immunodeficiency in Thailand and Taiwan. *N Engl J Med*. 2012;367(8):725–34.
- Chetchotisakd P, Kiertiburanakul S, Moosikapun P, Assanasen S, Chaiwarith R, Anunnatsiri S. Disseminated nontuberculous mycobacterial infection in patients who are not infected with HIV in Thailand. *Clin Infect Dis*. 2007;45(4):421–7.
- Wu UI, Holland SM. Host susceptibility to non-tuberculous mycobacterial infections. *Lancet Infect Dis*. 2015;15(8):968–80.
- Lake MA, Ambrose LR, Lipman MC, Lowe DM. Why me, why now? Using clinical immunology and epidemiology to explain who gets nontuberculous mycobacterial infection. *BMC Med*. 2016;14:54.
- Rosenzweig SD, Holland SM. Defects in the interferon-gamma and interleukin-12 pathways. *Immunol Rev*. 2005;203:38–47.
- Brown-Elliott BA, Woods GL. Antimycobacterial susceptibility testing of Nontuberculous Mycobacteria. *J Clin Microbiol*. 2019;57(10):e00834–19.
- Jennifer A, Shulha PD, Patricio Escalante MD, MSc; and, Wilson JW. MD. Pharmacotherapy Approaches in Nontuberculous Mycobacteria Infections. *Mayo Clin Proc*. 2019;94(8):1567–1581.
- Sharma SK, Upadhyay V. Epidemiology, diagnosis & treatment of non-tuberculous mycobacterial diseases. *Indian J Med Res*. 2020;152(3):185–226.
- Pfeffer PE, Hopkins S, Cropley I, Lowe DM, Lipman M. An association between pulmonary Mycobacterium avium-intracellulare complex infections and biomarkers of Th2-type inflammation. *Respir Res*. 2017;18(1):93.
- Patel SY, Ding L, Brown MR, Lantz L, Gay T, Cohen S, Martyak LA, Kubak B, Holland SM. Anti-IFN-gamma autoantibodies in disseminated nontuberculous mycobacterial infections. *J Immunol*. 2005;175(7):4769–76.
- Chi CY, Lin CH, Ho MW, Ding JY, Huang WC, Shih HP, Yeh CF, Fung CP, Sun HY, Huang CT, Wu TS, Chang CY, Liu YM, Feng JY, Wu WK, Wang LS, Tsai CH, Ho CM, Lin HS, Chen HJ, Lin PC, Liao WC, Chen WT, Lo CC, Wang SY, Kuo CY, Lee CH, Ku CL. Clinical manifestations, course, and outcome of patients with neutralizing anti-interferon-γ autoantibodies and disseminated nontuberculous mycobacterial infections. *Med (Baltim)*. 2016;95(25):e3927.
- Aoki A, Sakagami T, Yoshizawa K, Shima K, Toyama M, Tanabe Y, Moro H, Aoki N, Watanabe S, Koya T, Hasegawa T, Morimoto K, Kurashima A, Hoshino Y, Trapnell BC, Kikuchi T. Clinical significance of Interferon-γ neutralizing autoantibodies against disseminated Nontuberculous Mycobacterial Disease. *Clin Infect Dis*. 2018;66(8):1239–45.
- Vankayalapati R, Wize B, Samten B, Griffith DE, Shams H, Galland MR, Von Reyn CF, Girard WM, Wallace RJ Jr, Barnes PF. Cytokine profiles in immunocompetent persons infected with Mycobacterium avium complex. *J Infect Dis*. 2001;183(3):478–84.
- Wu UI, Chuang YC, Sheng WH, Sun HY, Zhong YT, Wang JY, Chang SC, Wang JT, Chen YC. Use of QuantiFERON-TB Gold In-tube assay in screening for neutralizing anti-interferon-γ autoantibodies in patients with disseminated nontuberculous mycobacterial infection. *Clin Microbiol Infect*. 2018;24(2):159–65.
- Chi CY, Chu CC, Liu JP, Lin CH, Ho MW, Lo WJ, Lin PC, Chen HJ, Chou CH, Feng JY, Fung CP, Sher YP, Li CY, Wang JH, Ku CL. Anti-IFN-γ autoantibodies in adults with disseminated nontuberculous mycobacterial infections are associated with HLA-DRB1*16:02 and HLA-DQB1*05:02 and the reactivation of latent varicella-zoster virus infection. *Blood*. 2013;121(8):1357–66.
- Pithukpakorn M, Roothumong E, Angkasekwinai N, Suktitipat B, Assawamakin A, Luangwedchakarn V, Umrod P, Thongnoppakhun W, Foongladda S, Suputtamongkol Y. HLA-DRB1 and HLA-DQB1 are Associated with Adult-Onset Immunodeficiency with Acquired Anti-interferon-gamma Autoantibodies. *PLoS ONE*. 2015;10(5):e0128481.
- Griffith DE, Aksamit T, Brown-Elliott BA, Catanzaro A, Daley C, Gordin F, Holland SM, Horsburgh R, Huitt G, Iademarco MF, Iseman M, Olivier K, Ruoss S, von Reyn CF, Wallace RJ Jr, Winthrop K, ATS Mycobacterial Diseases Subcommittee, American Thoracic Society, Infectious Disease Society of America. An official ATS/IDSA statement: diagnosis, treatment, and prevention of nontuberculous mycobacterial diseases. *Am J Respir Crit Care Med*. 2007;175(4):367–416.
- Daley CL, Iaccarino JM, Lange C, Cambau E, Wallace RJ Jr, Andrejak C, Böttger EC, Brozek J, Griffith DE, Guglielmetti L, Huitt GA, Knight SL, Leitman P, Marras TK, Olivier KN, Santin M, Stout JE, Tortoli E, van Ingen J, Wagner D, Winthrop KL. Treatment of Nontuberculous Mycobacterial Pulmonary Disease: an Official ATS/ERS/ESCMID/IDSA Clinical Practice Guideline. *Clin Infect Dis*. 2020;71(4):e1–36.
- Lange C, Böttger EC, Cambau E, Griffith DE, Guglielmetti L, van Ingen J, Knight SL, Marras TK, Olivier KN, Santin M, Stout JE, Tortoli E, Wagner D, Winthrop K, Daley CL; expert panel group for management recommendations in non-tuberculous mycobacterial pulmonary diseases. Consensus management recommendations for less common non-tuberculous mycobacterial pulmonary diseases. *Lancet Infect Dis*. 2022;22(7):e178–90.

Publisher's Note

Springer Nature remains neutral with regard to jurisdictional claims in published maps and institutional affiliations.