

## Video

# Intravitreal anti-vascular endothelial growth factor therapy in the treatment of vision loss associated with hematologic malignancy

Thomas P. Toohey<sup>a,\*</sup>, Jake Shortt<sup>b,c</sup>, Nevin John<sup>c,d</sup>, Salmaan Al-Qureshi<sup>e,f</sup>,  
Sanjeeva S. Wickremasinghe<sup>e,f</sup>

<sup>a</sup> Eastern Health, 5 Arnold Street, Box Hill, VIC, 3128, Australia

<sup>b</sup> Monash Haematology, Monash Health, 246 Clayton Road, Clayton, VIC, 3168, Australia

<sup>c</sup> Department of Medicine, School of Clinical Sciences at Monash Health, Faculty of Medicine, Nursing and Health Sciences, Monash University, Wellington Rd, Clayton, VIC, 3800, Australia

<sup>d</sup> Department of Neurology, Monash Health, 246 Clayton Road, Clayton, VIC, 3168, Australia

<sup>e</sup> Centre for Eye Research Australia (CERA), Level 7/32 Gisborne St, East Melbourne VIC 3002, Australia

<sup>f</sup> Royal Victorian Eye and Ear Hospital, 32 Gisborne Street, East Melbourne VIC 3002, Australia

## ARTICLE INFO

## Keywords:

Macular edema

Optic disc edema

Vascular endothelial growth factor

## ABSTRACT

**Purpose:** To determine the effectiveness of anti-vascular endothelial growth factor (VEGF) therapy in the setting of optic disc edema secondary to hematologic malignancies.

**Observations:** The report features two patients (one male, one female) in their 70's with biopsy proven hematologic malignancies who subsequently developed optic disc edema. The patients were commenced on a trial of successive intravitreal Aflibercept 2mg/0.05mL therapy. The best corrected visual acuity for patient 1 improved from 20/50 oculus dexter (OD) and 20/80 oculus sinister (OS), to 20/20 OD (4 lines Early Treatment of Diabetic Retinopathy Study (ETDRS)) and 20/32 OS (4 lines ETDRS). Similarly, patient 2's best corrected visual acuity improved from 20/100 OU to 20/50 OD (3 lines ETDRS) and 20/40 OS (4 lines ETDRS) following initiation of treatment. In addition, optical coherence tomography imaging obtained before and after therapy demonstrated an improvement in both patient's optic disc edema and cystoid macular edema.

**Conclusions and importance:** The findings of this report suggest that in patients with a known hematologic malignancy, optic disc edema and cystoid macular edema may be amenable to anti-VEGF treatment, especially if there are clinical and angiographic features of vascular endothelial growth factor overexpression.

## 1. Introduction

The disease pattern of hematologic malignancies can present within multiple organ systems including the eye and its related structures through systemic spread, through the side effects of hyperviscosity or via the overproduction of pro-inflammatory cytokines such as vascular endothelial growth factor (VEGF).<sup>1</sup> The finding of both optic disc edema (ODE) and cystoid macular edema (CME) has been identified as an uncommon ophthalmologic complication related to hematologic disorders.<sup>2</sup>

The management of ocular disease secondary to plasma cell disorders typically involves systemic therapy such as plasmapheresis or immunomodulatory and chemotherapy agents targeting the underlying malignant process directly.<sup>3</sup> The utility of anti-VEGF therapy remains an

unknown factor in managing ODE and CME secondary to lymphoproliferative or myeloid disorders. We present two cases of patients with a hematologic malignancy where anti-VEGF therapy was used to successfully treat optic disc edema and visually significant CME.

## 2. Findings

### 2.1. Case 1

A 73-year-old man with myelodysplastic syndrome with normal cytogenetics was referred after a routine optometry exam detected swelling of the right optic disc and scattered intraretinal hemorrhages in both eyes (Fig. 1). The patient was asymptomatic at the time, and his best corrected visual acuity (BCVA) was 20/20 in both eyes, with no

\* Corresponding author.

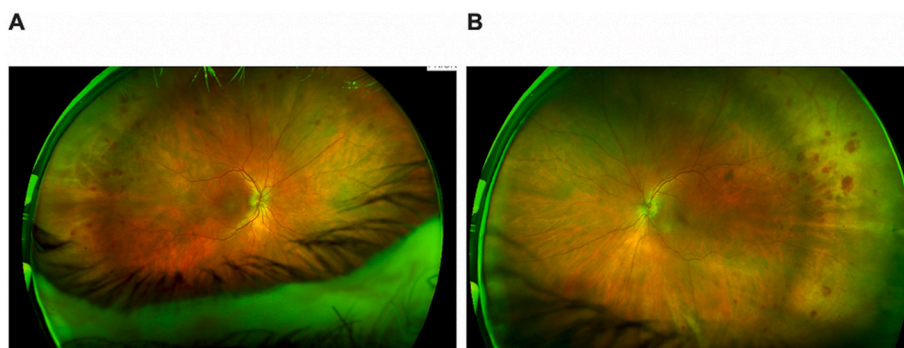
E-mail address: [tomtoohey93@gmail.com](mailto:tomtoohey93@gmail.com) (T.P. Toohey).

<https://doi.org/10.1016/j.ajoc.2024.102095>

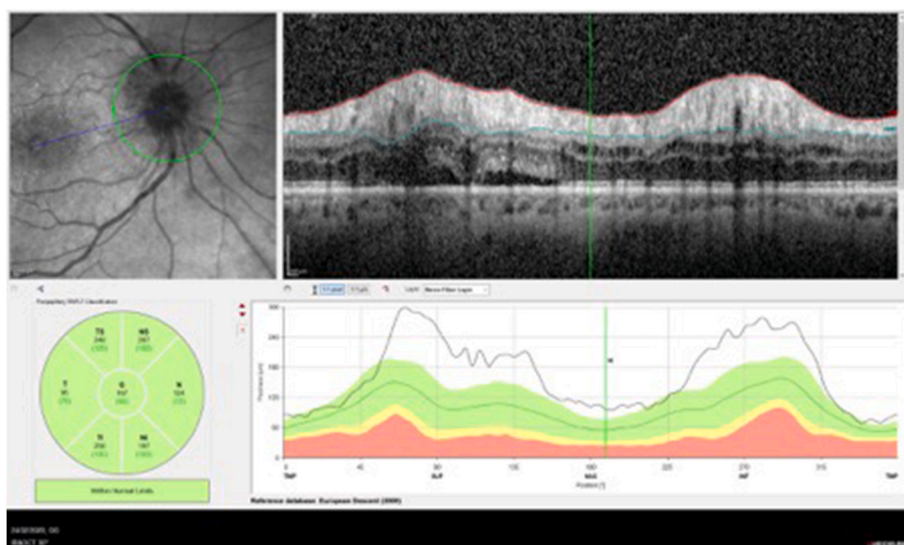
Received 1 March 2024; Received in revised form 4 June 2024; Accepted 17 June 2024

Available online 2 July 2024

2451-9936/© 2024 The Authors. Published by Elsevier Inc. This is an open access article under the CC BY-NC-ND license (<http://creativecommons.org/licenses/by-nc-nd/4.0/>).



**Fig. 1.** Widefield false color images of right (A) and left eye (B) of patient 1 showing disc edema in the right eye as well as bilateral peripheral intraretinal hemorrhages.



**Fig. 2.** Infra-red imaging and optical coherence tomography of the nerve fiber layer in patient 1 showing thickening in the right eye.

afferent pupillary defect. The right optic disc was swollen, but the left had a well-defined disc margin (Fig. 2). There was no spontaneous venous pulsation in the right eye, but the central retinal vein was easily collapsible with minimal digital pressure. Both eyes showed mild cystoid macular edema (CME), more apparent in the right eye (Fig. 3). There were scattered peripheral retinal hemorrhages in both eyes but his arterioles and venules were of normal caliber. Fundus fluorescein angiography (FFA) showed normal arm-to-eye time (17 seconds) and normal arteriovenous transit time (3 seconds), precluding the diagnosis of retinal venous occlusion. Both discs showed petaloid leak at the macula (Fig. 4). There were no features of peripheral capillary non-perfusion in the periphery in either eye.

Initial investigations demonstrated anemia, moderate neutropenia, and thrombocytopenia (hemoglobin 71 g/L, white cell count  $1.4 \times 10^9$ /L, and platelets  $47 \times 10^9$ /L). There were no blasts in the peripheral blood to suggest leukemic transformation and no evidence of paraprotein bands on protein electrophoresis, although there was rouleaux and red cell elongation with polychromasia. Magnetic resonance imaging (MRI) of the brain showed no evidence of optic nerve infiltration, and there was no space-occupying lesion or venous sinus thrombosis. Lumbar puncture was not performed due to the low platelet count, but the results of the blood film, imaging and bone marrow biopsy were consistent with myelodysplasia.

Given his lack of symptoms, he was initially treated conservatively, but over the following six months, the patient reported difficulty reading, and his BCVA dropped to 20/50 in the right eye and 20/80 in

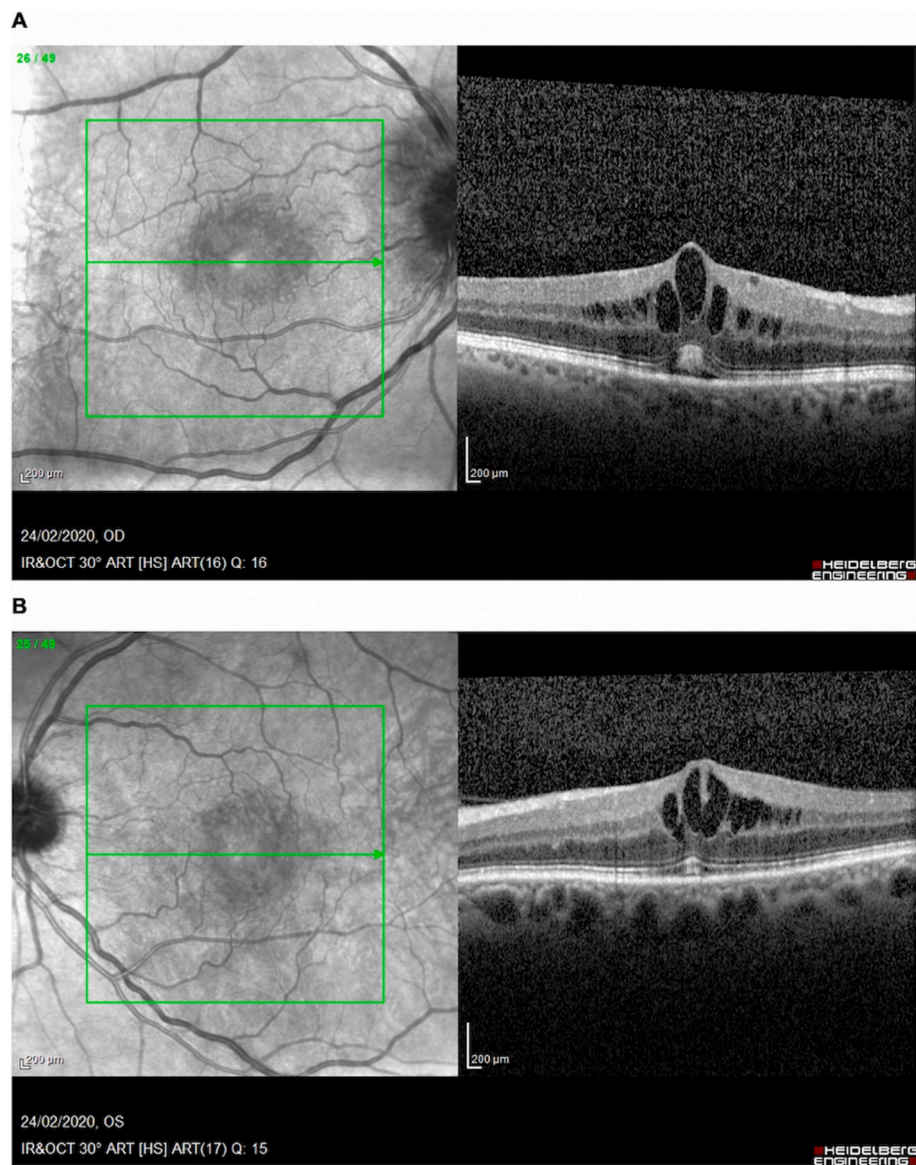
the left. The right optic disc remained swollen, and optical coherence tomography (OCT) examination demonstrated increased CME bilaterally. After consultation with his hematologist, plasmapheresis or immunomodulatory/chemotherapy agents were deemed to be inappropriate.

Accordingly, a trial of intravitreal Aflibercept 2mg/0.05mL was commenced in both eyes as he had evidence of peripheral retinal hemorrhages and leakage from the optic nerve capillaries on FFA, potentially suggesting vascular endothelial growth factor (VEGF) overexpression. One month after treatment, there was subjective visual improvement, and his BCVA was 20/63 in the right eye and 20/40 in the left (3 lines early treatment diabetic retinopathy study [ETDRS]), with considerable reduction in the CME. Five months after starting treatment, the patient's visual acuity had improved to 20/20 in the right eye (4 lines ETDRS) and 20/32 in the left (4 lines ETDRS), with a completely normal macular profile and nerve fiber layer on OCT.

There was a recurrence of CME upon cessation of anti-VEGF therapy and thus treatment was reinstated on a 'treat and extend' basis. At 31 months after the initial Aflibercept treatment the patient's visual acuity remained 20/25 in the right eye (5 lines ETDRS) and 20/20 in the left (4 lines ETDRS), with no optic disc edema, but he still requires Aflibercept injections in both eyes every 12–16 weeks (Fig. 5).

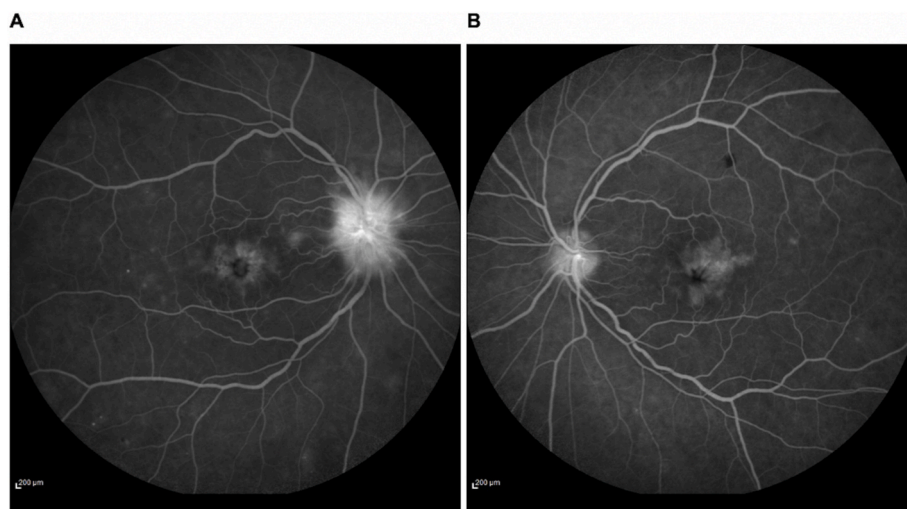
## 2.2. Case 2

A 77-year-old woman known to have Waldenstrom

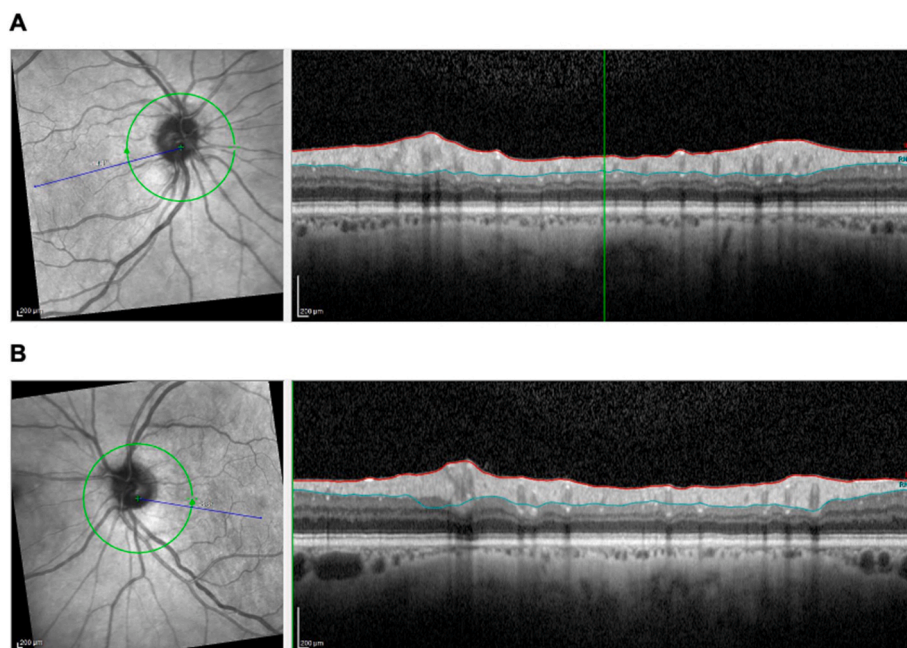


**Fig. 3.** Central raster optical coherence tomography of right (A) and left (B) eyes of patient 1 showing bilateral central intraretinal cystic edema within the inner nuclear layers and a small blister of subretinal fluid in the right eye.



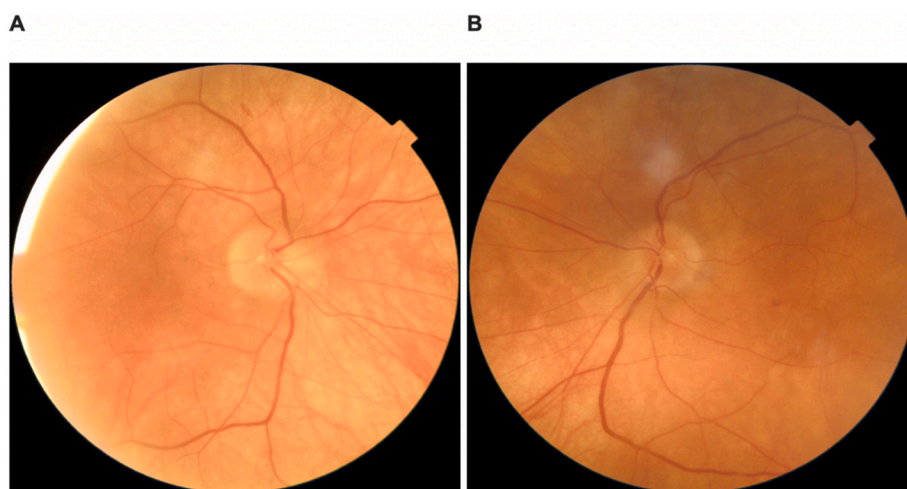


**Fig. 4.** Late phase fundus fluorescein angiography of right (A) and left (B) eyes of patient 1 showing disc leak and petaloid leak centrally.

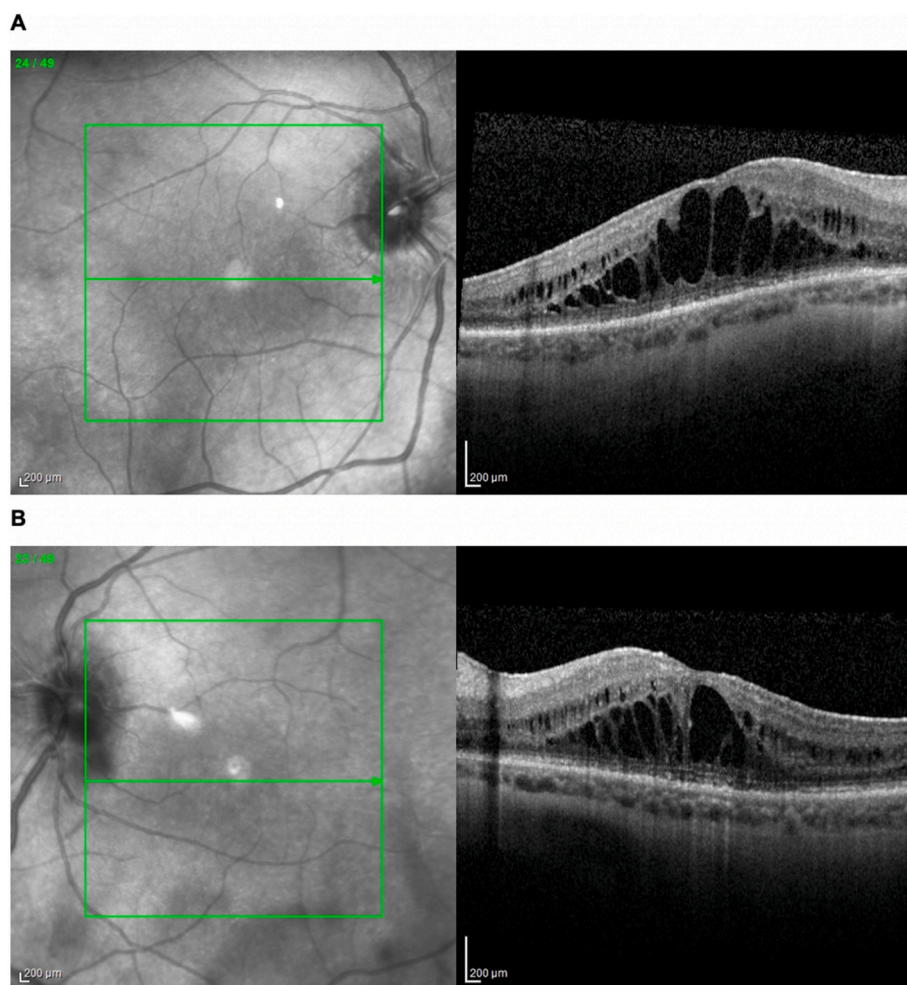


**Fig. 5.** Optical coherence tomography scans of the right (A) and left (B) eyes of patient 1 taken 31 months after commencing intravitreal Aflibercept treatment, showing a resolution of the patient's optic disc edema.





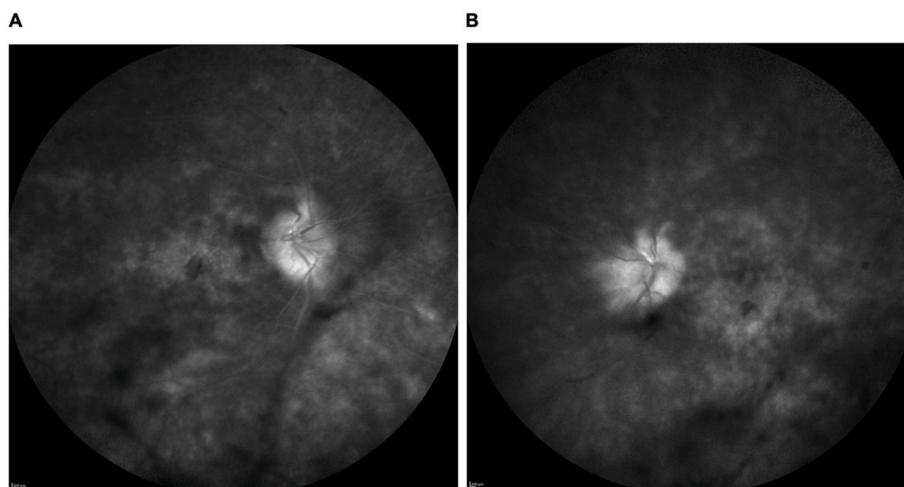
**Fig. 6.** Color fundus photographs of right (A) and left (B) eyes of patient 2 showing disc edema bilaterally. The right eye also has a nerve fiber layer hemorrhage superior to the vascular arcade.



**Fig. 7.** Central raster optical coherence tomography of right (A) and left (B) eyes of patient 2 showing bilateral central intraretinal cystic edema within the outer nuclear and inner nuclear layers.

macroglobulinemia (*MYD88*<sup>L265P</sup> mutation positive), complicated by peripheral neuropathy, renal infiltration, and B symptoms with a markedly elevated C-reactive protein (CRP) (135 mg/L) and IgM (19.7 g/L), presented with a 12-month history of progressively worsening visual acuity in both eyes. Two months prior to presentation, she had

completed Rituximab-based chemoimmunotherapy for worsening of lymphoma-related symptoms. At completion of systemic treatment, she was demonstrated to have achieved a complete metabolic response by FDG-PET scanning associated with moderate reduction in plasma par-protein and CRP levels. She had also received monthly intravenous



**Fig. 8.** Late phase fundus fluorescein angiography of right (A) and left (B) eyes of patient 2 showing disc leak and petaloid leak centrally.

immunoglobulin therapy as treatment for paraproteinaemic neuropathy. Her BCVA was 20/100 in each eye, and intraocular pressures were within normal limits. There was no evidence of intraocular inflammation in either eye, and she had clear media. Ophthalmoscopy demonstrated bilateral optic disc edema (ODE) and CME (Fig. 6) which was confirmed on OCT (Fig. 7). FFA disclosed an arteriovenous transit of 5 seconds and late frames showed disc leakage in both eyes, along with petaloid macular leakage (Fig. 8). Blood tests indicated mild neutropenia and thrombocytopenia with normal platelet morphology and hypomagnesemia (white cell count  $3.3 \times 10^9/L$ , platelets  $129 \times 10^9/L$ , magnesium 0.69 mmol/L). She had a raised erythrocyte sedimentation rate (98mm/hr) and CRP (77 mg/L), with a monoclonal IgM band (8 g/L).

MRI of the brain showed widespread pachymeningeal enhancement but no parenchymal involvement of the brain. Lumbar puncture was noncontributory, without evidence of leptomeningeal lymphoma. Due to the FFA findings suggesting VEGF overexpression, she was commenced on a trial of intravitreal Aflibercept 2mg/0.05mL in each eye. One month after treatment, she reported improvement in vision, and her acuities were measured as 20/80 in each eye (1 line ETDRS OU). The swelling of the optic discs had improved, as had the CME. Three further, monthly Aflibercept injections were administered, and her vision continued to improve, reaching 20/50 in the right eye (3 lines ETDRS) and 20/63 in the left (3 lines ETDRS). Subsequent treatment was given on a pro re nata basis based on her BCVA and macular appearance on OCT. One month prior to the initiation of Aflibercept therapy, she was also commenced on Zanubrutinib, a novel Bruton's tyrosine kinase (BTK) inhibitor used in the treatment of lymphoma.<sup>4</sup> The introduction of Zanubrutinib resulted in a complete biochemical response (IgM = 0.7 g/L) and normalization of CRP (3.8 mg/L) with further improvement in B symptoms and performance status. At nine months following initiation of Aflibercept treatment, she maintained 20/50 vision in the right eye (3 lines ETDRS) and 20/40 in the left (4 lines ETDRS), with a treatment interval of 10–12 weeks. Furthermore, subsequent examinations have demonstrated a reduction in optic disc swelling (Fig. 9).

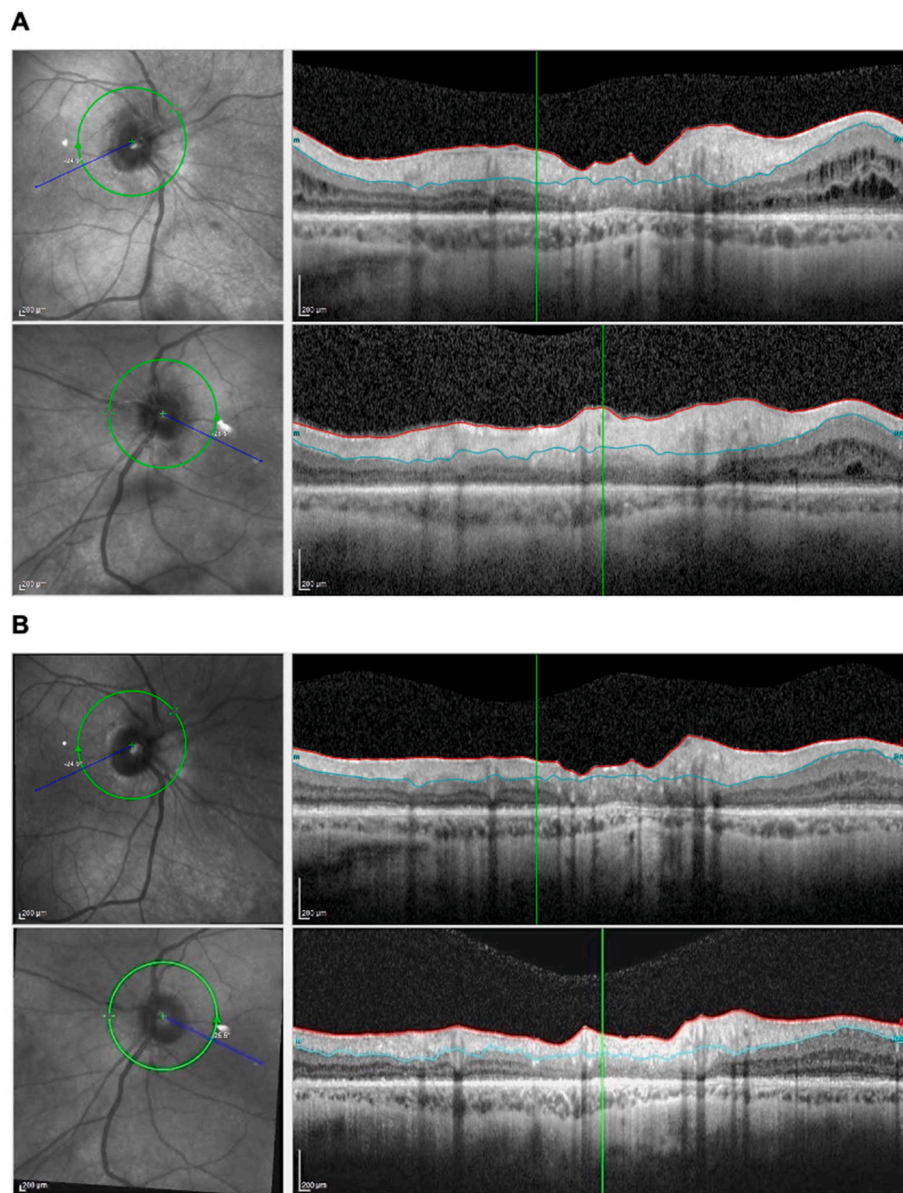
### 3. Discussion

The role of vascular endothelial growth factor (VEGF) in cancer progression is well documented. It has been found to promote angiogenesis and lymphangiogenesis, protect tumor cells from apoptosis, and increase vascular permeability via the opening of the inter-endothelial junctions. Overexpression of VEGF and its receptors has been identified in many hematologic tumor cells and bone marrow failure diseases, including acute myeloid leukemia and myelodysplastic syndrome.<sup>4</sup>

Within the eye, increased VEGF can lead to both cystoid macular edema (CME) and optic disc edema (ODE), as it causes the breakdown of the blood-retinal barrier by binding to leukocytes and initiating an acute inflammatory response.<sup>2</sup> Both of our patients showed signs of VEGF overexpression, with peripheral retinal hemorrhages and fundus fluorescein angiography (FFA) demonstrating leakage from the optic nerve capillaries with petaloid leak at the macula. This contrasts with the case detailed by Gass<sup>5</sup>, who described a patient with serous macular detachment associated with Waldenstrom macroglobulinaemia. There was no evidence of fluorescein leak on FFA, suggesting the serous detachment was unrelated to inner or outer retinal barrier disturbance, and thus he speculated that the subretinal fluid was related to abnormal serum proteins accumulating in the subretinal space. Baker<sup>6</sup> et al. also reported a further 4 cases of serous detachment associated with Waldenstrom macroglobulinaemia. In 3 of the 4 cases, the serous detachment was the predominant finding with no leak visible on FFA. These patients were treated with plasmapheresis and had mixed results with respect to vision and fluid resolution. The last case was similar to our patients in that the most apparent feature was that of CME with only a small blister of subretinal fluid. This patient also had petaloid leak on FFA and was successfully managed with 4–6 monthly triamcinolone acetonide injections.<sup>6</sup> Albeit less than monoclonal antibody inhibition of VEGF, corticosteroids have also been shown to have VEGF-lowering effects.<sup>7</sup>

It is possible that the etiology of the macular fluid may be multifactorial, and thus the treatment may vary depending on whether it relates to the accumulation of abnormal plasma proteins in the subretinal space or secondary to VEGF overexpression. In terms of VEGF production, multiple reports have also documented ODE and CME in the setting of polyneuropathy, organomegaly, endocrinopathy, monoclonal gammopathy, and skin changes (POEMS) syndrome, which is a paraneoplastic disorder characterized by increased secretion of pro-inflammatory cytokines such as VEGF, leading to increased vascular permeability and edema.<sup>8</sup> Although the clinical efficacy of using intravitreal anti-VEGF therapy as a treatment modality is yet to be extensively evaluated, favorable outcomes have been documented. Song and Yu<sup>8</sup> documented a case of ODE and CME successfully treated with intravitreal bevacizumab injections in a patient with POEMS syndrome. Similarly, Kim et al.<sup>9</sup> demonstrated a short-term reduction of ODE and CME following intravitreal anti-VEGF therapy in patients with POEMS syndrome, however the disease reoccurred within 50 days.

Another possible cause of raised VEGF in hematologic disease may relate to venous stasis from the production of paraproteins.<sup>1</sup> Hyperviscosity may impair blood flow through the retinal microvascular system, leading to venous stasis and thus hypoxia. Under such conditions, VEGF



**Fig. 9.** Optical coherence tomography of the right and left eyes of patient 2 before intravitreal Aflibercept (A), compared to the right and left eyes 16 months after starting treatment (B), demonstrating reduced bilateral optic disc edema.

is then upregulated. High levels of VEGF can additionally result in further leukocytic adhesion to the retinal endothelium. This process of leukocyte plugging may then exacerbate the retinal ischemia. It has been hypothesized that VEGF inhibition may facilitate the reopening of closed vessels and prevent the progression of non-perfusion by reducing leukostasis and facilitating vascular perfusion within the retina.<sup>10</sup>

The findings of this report suggest that in patients with a known hematologic malignancy, ODE and CME may be amenable to anti-VEGF treatment in some cases, especially if there are clinical and angiographic features of VEGF overexpression.

### 3.1. Patient consent

The case report and its contents, including the results of investigations, was discussed with the patients, and informed consent for publication was obtained.

Institutional approval was not required.

### Funding

No funding or grant support.

### Authorship

All authors attest that they meet the current ICMJE criteria for Authorship.

### CRediT authorship contribution statement

**Thomas P. Toohey:** Writing – original draft, Data curation. **Jake Shortt:** Writing – review & editing, Investigation. **Nevin John:** Investigation. **Salmaan Al-Qureshi:** Writing – review & editing, Validation. **Sanjeewa S. Wickremasinghe:** Supervision, Methodology, Conceptualization.



## Declaration of competing interest

The authors declare that they have no known competing financial interests or personal relationships that could have appeared to influence the work reported in this paper.

## Acknowledgements

None.

## References

1. Rajagopal RMDP, Rsmddp Apte. Seeing through thick and through thin: retinal manifestations of thrombophilic and hyperviscosity syndromes. *Surv Ophthalmol*. 2016;61(2):236–247.
2. Chong DY, Comer GM, Trobe JD. Optic disc edema, cystoid macular edema, and elevated vascular endothelial growth factor in a patient with POEMS syndrome. *J Neuro Ophthalmol*. 2007;27(3).
3. Buske C, Hoster E, Hess G, et al. The addition of rituximab to front-line therapy with CHOP (R-CHOP) results in a higher response rate and longer time to treatment failure in patients with lymphoplasmacytic lymphoma: results of a randomized trial of the German Low-Grade Lymphoma Study Group (GLSG). *Leukemia*. 2009;23(1):153–161.
4. Tam CS, Opat S, D'Sa S, et al. A randomized phase 3 trial of zanubrutinib vs ibrutinib in symptomatic Waldenström macroglobulinemia: the ASPEN study. *Blood*. 2020;136(18):2038–2050.
5. Gass JDM. *Stereoscopic Atlas of Macular Diseases: Diagnosis and Treatment*. second ed. St Louis, MO: Mosby; 1997.
6. Baker PS, Garg SJ, Fineman MS, et al. Serous macular detachment in waldenström macroglobulinemia: a report of four cases. *Am J Ophthalmol*. 2013;155(3):448–4455.0.
7. Sohn HJ, Han DH, Kim IT, et al. Changes in aqueous concentrations of various cytokines after intravitreal triamcinolone versus bevacizumab for diabetic macular edema. *Am J Ophthalmol*. 2011;152(4):686–694.
8. Song HB, Yu HG. Optic disc edema responding to localized anti-vascular endothelial growth factor treatment in a patient with POEMS syndrome. *Kor J Ophthalmol*. 2015;29(5):357–358.
9. Kim DW, Kang SY, Bae HW, Hong S, Seong GJ, Kim CY. Intravitreal bevacizumab for the treatment of optic disc edema in a patient with POEMS syndrome. *Kor J Ophthalmol*. 2015;29(5):354–356.
10. Liu Y, Shen J, Fortmann SD, Wang J, Vestweber D, Campochiaro PA. Reversible retinal vessel closure from VEGF-induced leukocyte plugging. *JCI insight*. 2017;2(18). <https://doi.org/10.1172/jci.insight.95530>.