

# Cataract surgery complications in a patient with brittle cornea syndrome and Ehlers-Danlos syndrome type six: A case report

Vincenzo Maurino<sup>a</sup>, Francesco Aiello<sup>b</sup>, Francesco Matarazzo<sup>c,\*</sup>

<sup>a</sup> Cornea and External Disease Service, Moorfields Eye Hospital, London, UK

<sup>b</sup> Ophthalmology Unit, Department of Experimental Medicine, University of Rome "Tor Vergata", Rome, Italy

<sup>c</sup> Department of Physics "Ettore Pancini", University of Naples "Federico II", Naples, Italy

## ARTICLE INFO

### Keywords:

Cataract surgery  
Ehlers-Danlos syndrome  
Brittle cornea syndrome  
Keratoglobus  
Intraoperative complications  
Postoperative management

## ABSTRACT

**Purpose:** This case report delineates the intricacies and challenges encountered in cataract surgery in Ehlers-Danlos syndrome type VI presenting with advanced Keratoglobus (KG), severe cataract and brittle cornea.

**Observations:** Despite meticulous planning and intraoperative precautions, including phacoemulsification with reduced intraocular pressure (low bottle height), the patient experienced corneal ruptures necessitating a shift to Extra Capsular Cataract Extraction (ECCE). Postoperative management involved corneal suturing and vigilant follow-up.

**Conclusions and Importance:** Cataract surgery in patients with brittle cornea poses significant challenges due to extreme corneal fragility. Exhaustive pre-operative assessment, careful intraoperative techniques, and vigilant postoperative care are paramount for successful outcomes in these complex cases.

## 1. Introduction

Blue sclera and brittle cornea are ocular manifestations associated with genetic collagen disorders.<sup>1–3</sup> Blue sclera, often observed in connective tissue disorders like Ehlers-Danlos syndrome and Marfan syndrome, correlates with a significant reduction in central corneal thickness.<sup>1,2</sup> Brittle Cornea Syndrome (BCS) is a rare autosomal recessive connective tissue disorder characterized by progressive corneal thinning, progressive myopia, and the presence of keratoconus or keratoglobus and blue sclera, resulting in an increased susceptibility for cornea and globe perforation and rupture. It was first described by Dr. Richard Stein in 1968 when he encountered corneas breaking into “crumbs” during suturing attempts following perforation.<sup>4</sup> BCS can occur independently or in association with Ehlers-Danlos Syndrome Type Six (EDS VI). EDS VI is distinguished by additional features including severe muscular hypotonia at birth, progressive kyphoscoliosis starting in early infancy, skin fragility with abnormal scarring, severe joint hypermobility and luxations, a Marfanoid habitus, osteopenia, arterial rupture, and early mortality due to cardiopulmonary insufficiency.<sup>5</sup> These distinct clinical features allow for differentiation between BCS and EDS VI. Genetic testing confirms the diagnosis, especially in cases with positive consanguinity.<sup>3</sup>

Early identification of patients with brittle cornea is crucial for visual prognosis.<sup>3,6</sup> Preventive measures such as protective eyewear and lifestyle modifications are essential to mitigate the risk of corneal perforation after trivial trauma, which can lead to blindness at a young age.<sup>3,6</sup> Cataract surgery in individuals with blue sclera and brittle cornea poses significant challenges and should be carefully considered after thorough examination and counselling.<sup>1,6</sup> We aim to present a unique case of corneal rupture during phacoemulsification in a patient with EDS type VI and brittle cornea.

## 2. Case report

We present the case of a 73-year-old woman who was referred to us with a diagnosis of Ehlers-Danlos syndrome type VI confirmed by tests done in the past. She presented with brittle cornea and blue sclera, severe pulmonary disease and kyphosis, rendering her difficult to lie flat. Additionally, she had a history of childhood trauma resulting in the loss of her right eye, for which she wore a prosthetic. Her left eye exhibited advanced Keratoglobus (KG), accompanied by a brunescant cataract, leading to worsening vision (Fig. 1). Her best-corrected visual acuity (BCVA) had decreased over the years to 1/60, and this was attributed to worsening cataract. Due to her complex ocular condition, she had been

\* Corresponding author. Department of Physics “Ettore Pancini”, University of Naples “Federico II”, Naples, Italy.

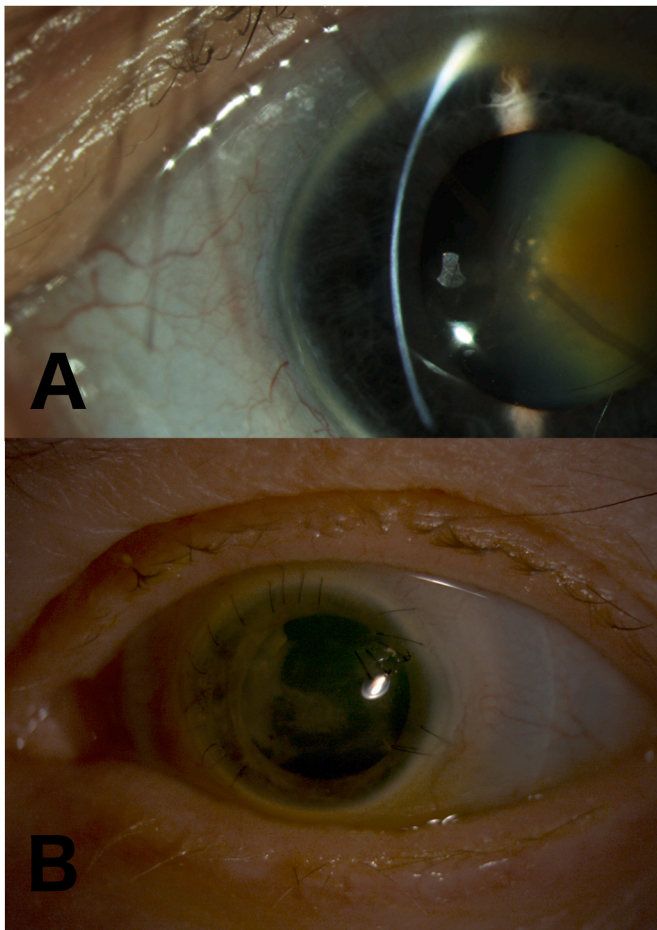
E-mail address: [francesco.matarazzo@unina.it](mailto:francesco.matarazzo@unina.it) (F. Matarazzo).

<https://doi.org/10.1016/j.ajoc.2024.102120>

Received 15 April 2024; Received in revised form 24 June 2024; Accepted 6 July 2024

Available online 18 July 2024

2451-9936/© 2024 Published by Elsevier Inc. This is an open access article under the CC BY-NC-ND license (<http://creativecommons.org/licenses/by-nc-nd/4.0/>).



**Fig. 1.** **A)** Pre-operative photograph. The image shows advanced Keratoglobus (KG) with a brunescent cataract. **B)** Post-operative photograph. The image depicts the eye after surgery, with multiple sutures visible on the cornea. A Bandage Contact Lens (BCL) is in situ to aid in corneal healing and protection.

listed for complex left eye cataract surgery under local anaesthesia. The biometry keratometry data were unreliable due to her corneal condition. Axial length measurements were 30.24 mm with optical biometer and 30.1 mm with ultrasound A-scan biometry. Pentacam (Oculus, Wetzlar, Germany) scans indicated advanced ectasia with steep Ks (Fig. 2); thus, we selected a +7.0 Diopters (D) Intraocular Lens (IOL) based on Watson et al. article,<sup>7</sup> using a standard K value of 43.25 D with a mean target refraction of  $-1.8$  D.

Considering the difficulties posed by the patient's general health kyphoscoliosis and COPD and her ocular condition, we approached the case with careful planning. Limbal incisions were considered to improve surgical access and visualization, with the primary incision positioned supero-temporally, performed with a 2.4 mm keratome. Continuous curvilinear capsulorhexis under viscoelastic and hydrodissection were performed uneventfully. Phaco machine was set reducing the bottle height to mitigate intraocular pressure and diminish the likelihood of complications and the infero-temporal side port was sutured with 10.0 nylon as it was slightly leaking.

Despite the precautions taken, shortly after the insertion of the phaco-tip and initiation of irrigation, the cornea experienced both radial and tangential irregular spontaneous ruptures (Video 1). Consequently, phacoemulsification could not be continued, prompting the surgeon to convert to Extra Capsular Cataract Extraction (ECCE) for cataract removal. The original main incision was sutured with 10.0 nylon under viscoelastic, while a new limbal wound was created superiorly and nasally for approximately  $150^\circ$ , using a feather blade and a crescent

angled knife, aiming for a three-step incision as feasible. Nucleus extraction was performed through the primary wound with an irrigating vectis, and Soft Lens Material was removed using a Simcoe cannula. It was decided not to implant an IOL and to leave the patient aphakic. Subsequently, corneal suturing was initiated, which proved to be exceptionally challenging due to tissue friability. Despite the placement of a total of 19 sutures, leakage persisted from the ruptured area, necessitating the application of fibrin glue. At the conclusion of the procedure, Intracameral Cefuroxime was administered, followed by the placement of a Bandage Contact Lens (BCL).

The day after surgery the patients had a flat anterior chamber two days after the complex cataract procedure and hence had to be taken back to the OR for more suturing and corneal gluing with cyanoacrylate glue. On day two post-surgery, the patient presented with Hand Motion vision alongside mild corneal oedema, yet with well-placed sutures and a stable anterior chamber with bandage contact lens (BCL) in situ. Treatment included a regimen of preservative-free topical corticosteroids and antibiotics (1 mg/ml dexamethasone four times daily and 0.5 % chloramphenicol four times daily, respectively). By week one (Fig. 1), there was a persistently stable anterior chamber without evidence of leakage (Seidel negative). One month post-surgery, there was a slight improvement in visual acuity to 1/60. Sutures remained intact and she started tapering down steroid drops to once weekly and but continued with Preservative Free antibiotic therapy since the BCL was kept in situ for many months. The patient was provided with a protective transparent eye shield to wear at all the time given the eye fragility.

The patient received regular follow-up appointments during the first two year post-surgery. Sutures were meticulously removed at the slit-lamp during these visits, with the final suture being taken out at the 24-month mark following the surgery. At the conclusive follow-up, the patient exhibited a best-corrected visual acuity (BCVA) of 6/60 with  $+1.00/-1.00 \times 180$ , alongside a quiescent anterior chamber status, Aphakia, and myopic atrophic changes evident upon fundoscopic examination.

### 3. Discussion

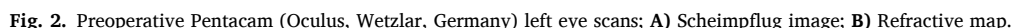
Cataract surgery in patients with blue sclera and brittle cornea presents significant challenges due to the inherent fragility and thinning of the cornea, as well as potential complications associated with collagenopathies.<sup>1-4</sup> Our case report highlights the complexities involved in managing cataract surgery in such patients and underscores the importance of careful pre-operative planning, intraoperative techniques, and postoperative watchfulness.

Patients with blue sclera often present with osteoarticular manifestations such as kyphosis and scoliosis, which can limit surgical positioning and render surgery more challenging or even impossible.<sup>6</sup> Therefore, detailed pre-operative assessment of the patient's musculoskeletal condition is essential to ensure adequate positioning during surgery. Additionally, diagnostic tools such as Scheimpflug tomography scan and anterior segment optical coherent tomography (AS-OCT) play a crucial role in assessing corneal irregularities, astigmatism, and scleral thinning, guiding the clinician towards appropriate therapeutic interventions.<sup>8</sup>

IOL selection in patients with advanced ectasia is challenging due to the overestimation or impossibility of obtaining reliable K readings.<sup>8</sup> Using standard K values, such as 43.25 D, can help achieve a myopic target, leading to more predictable outcomes. Postoperatively, patients often require contact lenses, and having a negative refraction simplifies fitting. Watson et al. demonstrated that using standard K values resulted in a lower biometry prediction error and better outcomes for patients needing scleral lenses, highlighting the benefit of this approach for easier postoperative management.<sup>7</sup>

Surgical planning for cataract surgery in patients with EDS VI must address several key challenges, including brittle cornea with thinning and ectasia, possible lens dislocation, and adequate surgical positioning.





During surgery, maintaining IOP below 20 mmHg is important to avoid corneal ruptures. Surgeons should be prepared to address lens instability and zonular weakness, which are common in patients with collagenopathies. The use of cyanoacrylate glue, 10-0 nylon sutures, and bandage contact lenses should be readily available to manage any wound rupture effectively. Postoperative care involves vigilant monitoring for signs of wound leakage, active leaks, and anterior chamber

## 4. Conclusion

In conclusion, our case underscores the importance of meticulous planning and careful consideration in managing cataract surgery in patients with Ehlers-Danlos syndrome type IV (EDS VI) and brittle cornea syndrome (BCS). Despite our best efforts to mitigate

intraoperative complications, including maintaining intraocular pressure (IOP) and selecting appropriate surgical techniques, we encountered challenges related to corneal fragility and thinning, ultimately necessitating a conversion to Extra Capsular Cataract Extraction (ECCE) due to corneal rupture.

Our experience highlights the need for comprehensive pre-operative assessment, including evaluation of musculoskeletal abnormalities and corneal irregularities, to tailor surgical approaches to each patient's unique needs. Intraoperative vigilance and preparedness for unexpected complications, such as corneal ruptures, are essential in managing these challenging cases effectively. The inherent fragility of the cornea in these patients necessitates caution and careful consideration of surgical risks and benefits.

#### Patient consent to publish

The patient described in this report granted their verbal consent to publish this case report and images contained within.

#### CRedit authorship contribution statement

**Vincenzo Maurino:** Writing – review & editing, Writing – original draft, Validation, Supervision, Methodology, Investigation, Data curation, Conceptualization. **Francesco Aiello:** Writing – review & editing, Writing – original draft, Validation, Data curation, Conceptualization. **Francesco Matarazzo:** Writing – review & editing, Writing – original draft, Visualization, Validation, Methodology, Investigation, Data curation, Conceptualization.

#### Declaration of competing interest

The authors declare that they have no known competing financial interests or personal relationships that could have appeared to influence

the work reported in this paper.

#### Acknowledgements & disclosures

None.

#### Appendix A. Supplementary data

Supplementary data related to this article can be found at <https://doi.org/10.1016/j.ajoc.2024.102120>.

#### References

1. Esfandiari H, Ansari S, Mohammad-Rabei H, Mets MB. Management strategies of ocular abnormalities in patients with marfan syndrome: current perspective. *J Ophthalmic Vis Res.* 2019 Jan-Mar;14(1):71–77.
2. Swierkowska J, Gajeczka M. Genetic factors influencing the reduction of central corneal thickness in disorders affecting the eye. *Ophthalmic Genet.* 2017 Dec;38(6):501–510.
3. Burkitt Wright EM, et al. Brittle cornea syndrome: recognition, molecular diagnosis and management. *Orphanet J Rare Dis.* 2013 May 4;8:68.
4. Stein R, Lazar M, Adam A. Brittle cornea: a familial trait associated with blue sclera. *Am J Ophthalmol.* 1968;66(1):67–69. [https://doi.org/10.1016/0002-9394\(68\)91789-3](https://doi.org/10.1016/0002-9394(68)91789-3). ISSN 0002-9394.
5. Al-Hussain H, Zeisberger SM, Huber PR, Giunta C, Steinmann B. Brittle cornea syndrome and its delineation from the kyphoscoliotic type of Ehlers-Danlos syndrome (EDS VI): report on 23 patients and review of the literature. *Am J Med Genet.* 2004 Jan 1;124A(1):28–34. <https://doi.org/10.1002/ajmg.a.20326>. PMID: 14679583.
6. Walkden A, Burkitt-Wright E, Au L. Brittle cornea syndrome: current perspectives. *Clin Ophthalmol.* 2019 Sep 25;13:1895–1896.
7. Watson MP, Anand S, Bhogal M, et al. Cataract surgery outcome in eyes with keratoconus. *Br J Ophthalmol.* 2014 Mar;98(3):361–364. <https://doi.org/10.1136/bjophthalmol-2013-303829>. Epub 2013 Aug 21. PMID: 23966369.
8. Aiello F, Nasser QJ, Nucci C, Angunawela RI, Gatziofias Z, Maurino V. Cataract surgery in patients with keratoconus: pearls and pitfalls. *Open Ophthalmol J.* 2017 Jul 31;11:194–200. <https://doi.org/10.2174/1874364101711010194>. PMID: 28932335; PMCID: PMC5585461.