

A comprehensive long-term follow-up study of Brown-McLean syndrome

Yasufumi Tomioka^a, Hiroshi Tanaka^a, Chie Sotozono^a, Shigeru Kinoshita^{b,*}

^a Department of Ophthalmology, Kyoto Prefectural University of Medicine, Kyoto, Japan

^b Department of Frontier Medical Science and Technology for Ophthalmology, Kyoto Prefectural University of Medicine, Kyoto, Japan

ARTICLE INFO

Keywords:

Brown-McLean syndrome
Corneal endothelial cells
Corneal endothelial failure
Multiple intraocular surgeries
Slit-scanning wide-field contact specular microscope

ABSTRACT

Purpose: This report aims to document a long-term follow-up of a rare case of Brown-McLean syndrome where high-density central corneal endothelial cells (CECs) were maintained, yet the peripheral area developed corneal edema.

Observations: A 72-year-old Japanese male was referred to our hospital. He had a history of three instances of rhegmatogenous retinal detachment in the right eye, requiring three intraocular surgeries. While the circumferential corneal peripheral regions, predominantly in the nasal and temporal areas, exhibited corneal edema, the central region remained clear. The central corneal thickness was measured at 541 μm , and the thickness in the nasal and temporal regions exceeded 700 μm . CEC density at the center was determined to be 2499 cells/ mm^2 using a non-contact specular microscope, but imaging of the nasal and temporal cornea was obscure due to corneal edema. Panoramic images of the corneal endothelial layer, captured via slit-scanning wide-field contact specular microscopy, showed a high-density and uniform distribution of cells across the clear corneal region, close to the border between edematous and non-edematous areas. Twelve years after the initial visit, the central cornea maintained its transparency and a CEC density of 2456 cells/ mm^2 . Despite the entire peripheral corneal edema, there was no noted deterioration from twelve years prior. The annual reduction in central cornea CECs was a mere 0.09 %.

Conclusions and importance: This case implies the unintended formation of a biological barrier at the border or a possible lack of CEC affinity of centrifugal movement, among other unidentified factors. Such factors may hinder the migration of CECs from the central to the peripheral regions of the cornea, a discovery that is crucial for advancing our knowledge of corneal endothelial biology and exploring new treatment options.

1. Introduction

Corneal endothelial cells (CECs) are pivotal in maintaining corneal transparency by regulating the fluid exchange between the aqueous humor and the corneal stroma, a process essential for the homeostasis of corneal clarity.¹ CECs exhibit limited proliferative capacity.² A reduction in their density below 400 cells/ mm^2 , often due to surgical trauma from intraocular procedures or diseases like Fuchs endothelial corneal dystrophy, can result in corneal endothelial dysfunction.^{3,4} This may progress to central corneal endothelial failure, causing significant visual impairment. While such scenarios are common, instances of peripheral corneal edema are rare. Brown-McLean Syndrome (BMS)⁵ is one such condition, thought to be linked to intracapsular cataract extraction or multiple intraocular surgeries. Although literature indicates that the central cornea in BMS remains clear for a prolonged period,^{6–8} there is a

lack of detailed, long-term follow-up or theoretical explanation of its endothelial behavior.

Understanding the in vivo distribution of CECs is vital for comprehending their kinetics and pathology. Traditional methods like non-contact specular microscopy or confocal microscopy provide limited insights into CEC characteristics, such as cell size and morphology, due to their restricted area coverage and discontinuous nature.^{9–11} In contrast, slit-scanning wide-field contact specular microscopy allows for the observation of a continuous, wide-field area. This technique facilitates the creation of panoramic images, enabling comparative analysis of central and peripheral regions and offering a more comprehensive understanding of CEC distribution and behavior.¹²

Therefore, employing this advanced imaging technology, this BMS case report seeks to illuminate a unique CEC manifestation. In this instance, despite the high CEC density maintaining central corneal

* Corresponding author. Department of Frontier Medical Science and Technology for Ophthalmology, Kyoto Prefectural University of Medicine, 465 Kajii-cho, Hirokoji-agaru, Kawaramachi-dori, Kamigyo-ku, Kyoto, 602-0841, Japan.

E-mail address: fmstoph@koto.kpu-m.ac.jp (S. Kinoshita).

<https://doi.org/10.1016/j.ajoc.2024.102146>

Received 27 February 2024; Received in revised form 6 June 2024; Accepted 14 August 2024

Available online 22 August 2024

2451-9936/© 2024 Published by Elsevier Inc. This is an open access article under the CC BY-NC-ND license (<http://creativecommons.org/licenses/by-nc-nd/4.0/>).

clarity, the surrounding 360-degree peripheral corneal area developed edema without any observable CEC image. Remarkably, this high CEC density in the central cornea has been maintained for over twelve years since the initial consultation.

2. Case report

A 72-year-old Japanese male was referred to the Department of Ophthalmology at Kyoto Prefectural University of Medicine, Kyoto, Japan, in April 2012. He had experienced rhegmatogenous retinal detachments in his right eye over 50 years ago, and underwent three intraocular surgeries 40 to 35 years ago, resulting in an aphakic eye with iris damage, and corneal edema developed around 2005. Additionally, he developed corneal edema accompanied by epithelial bullae around the entire peripheral cornea, predominantly in the nasal and temporal regions (Fig. 1A B). The central cornea thickness measured 541 μm , while the thickness in the nasal and temporal mid-peripheral region exceeded 700 μm by use of a rotating Scheimpflug imaging-system camera (Pentacam HR; Oculus Optikgerate GmbH). The CEC density was assessed at 2499 cells/ mm^2 without any guttae appearance by non-contact specular microscope (EM-4000™ Tomey Corporation, Japan). However, the specular microscopic image at the nasal and temporal cornea was obscured due to the corneal edema. A panoramic image captured by a slit-scanning wide-field contact specular microscope (CellChek™; Konan Medical, Japan) revealed high CEC density and uniform cell distribution in the clear cornea regions, extending up to the border between the edematous and non-edematous areas (Fig. 2). The best correct visual acuity and the intraocular pressure (IOP) in his right eye were 20/80, and 10 mmHg. The cornea and IOP in his left eye were within normal range.

Twelve years following the initial consultation, the central region of the cornea continued to exhibit transparency, with a CEC density of 2456 cells/ mm^2 without cornea guttae. Despite the presence of peripheral corneal edema, there was no deterioration compared to the state twelve years prior (Fig. 1C D). Remarkably, the annual reduction rate of CECs in the central cornea was 0.09 % (Fig. 3), indicating a minimal decrease in CEC density and suggesting a stable environment in

the anterior chamber. Notably, no migration of cells into the edematous peripheral corneal area was observed.

3. Discussion

We encountered a rare case of BMS where, despite the presence of corneal edema in the peripheral region, the central CEC density remained high, thus preserving corneal transparency. Impressively, even after twelve years, both the transparency and CEC density in the central region were maintained, with no further progression of edema in the peripheral region.

In this study, we observed that while the center of cornea remained transparent, the peripheral cornea exhibited edema due to corneal endothelial failure. Commonly, an enlargement or undetectable image of CECs is first observed in the central region in Fuchs endothelial corneal dystrophy. This led us to hypothesize a gradual decrease in CEC density from the center towards the periphery. Contrary to our expectations, however, we found that high-density CECs were present not only in the center but also in the mid-periphery via non-contact specular microscope.

Using a slit-scanning wide-field contact specular microscope, we were able to capture continuous wide-field images from one edge of the cornea to the other, provided that corneal transparency is maintained. In this particular case, CEC density exceeded 2000 cells/ mm^2 in all transparent regions, including the area close to the border between edematous and non-edematous regions. This was observed despite the speculated endothelial cell damage on both the nasal and temporal side. Significantly, the observation revealed a consistent, high-density distribution of CECs within the border, yet the likelihood of this being sustained through cell proliferation appears improbable.

According to various studies,^{13,14} significant regional differences in endothelial cell density have been noted for several years post-cataract surgery. This evidence indicates that heterogeneity in CEC distribution in vivo can occur and be sustained following acute CEC loss due to factors like cell migration, even in the absence of significant cell proliferation. CEC confluence is typically maintained by contact inhibition, which is demarcated by Schwalbe's line in normal subjects,¹⁵ marking the corneal border and the termination of Descemet's membrane. In this case, we hypothesize that a Schwalbe's line-like structure might have inadvertently formed in the peripheral area or that the presence of disintegrated cells could be preventing the migration of CECs from the center to the periphery. Alternatively, the other hypothesis is that CECs may be a preferable movement of centripetal, but not centrifugal.

4. Conclusions

This case introduces the possibility of a biological structure similar to Schwalbe's line having developed in the peripheral area, or that CECs may exhibit a preference for centripetal movement, or other unknown factors. Should the former scenario be confirmed, it presents the intriguing potential of intentionally creating a comparable mechanical barrier in future therapeutic approaches. In the context of endothelial biology, it is crucial to explore the underlying reasons for the impaired migration of CECs from the central to the peripheral regions.

Patient consent

Consent to publish this case report has been obtained from the patient in writing. This report does not contain any personal information that could lead to the identification of the patient. The protocols of this study were approved by the Institutional Review Board and the Ethics Committee of Kyoto Prefectural University of Medicine (Approval No. ERB-C-1235-3), and all procedures were performed in accordance with the tenets set forth in the Declaration of Helsinki.

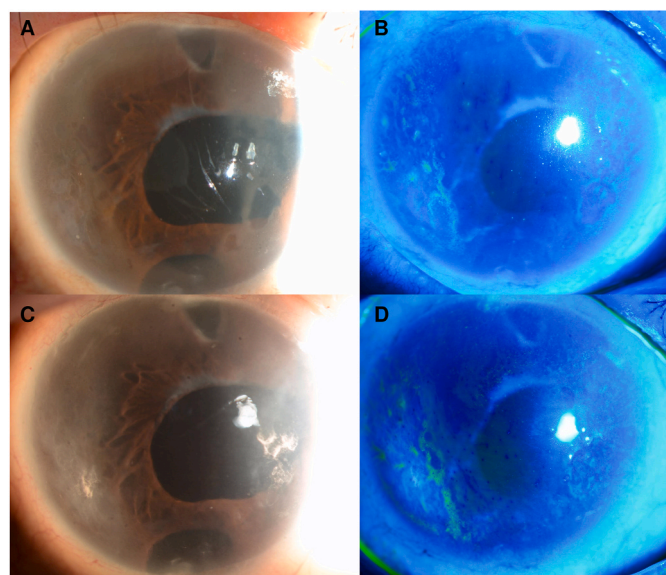


Fig. 1. Slit-lamp photographs of the right eye at the initial referral visit and twelve years later. At initial visit, the central part of the cornea showed no edema, while peripheral corneal edema was evident (A, B). Initially, the central cornea measured 541 μm in thickness, and the peripheral cornea exceeded 700 μm . Twelve years later, the photographs revealed no progression in the corneal edema (C, D). The central cornea thickness was 557 μm , while the peripheral thickness remained over 700 μm .

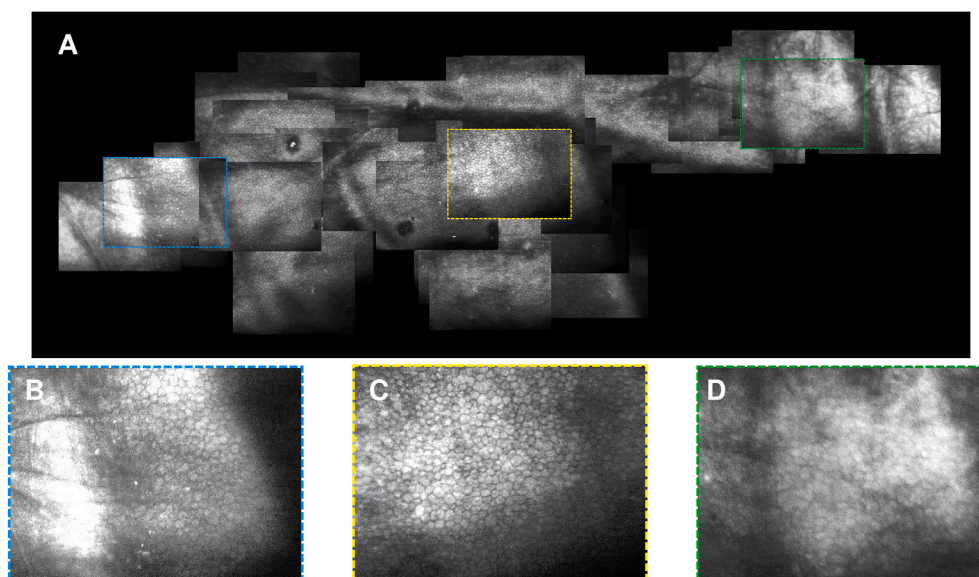


Fig. 2. Representative panoramic images created by a slit-scanning wide-field contact specular microscope (CellChek™; Konan Medical, Japan) (A). Magnified images showcase the nasal peripheral (B), central (C), and temporal peripheral (D) regions. The peripheral regions are close to the border of the corneal edema (Scale bar = 100 μ m).

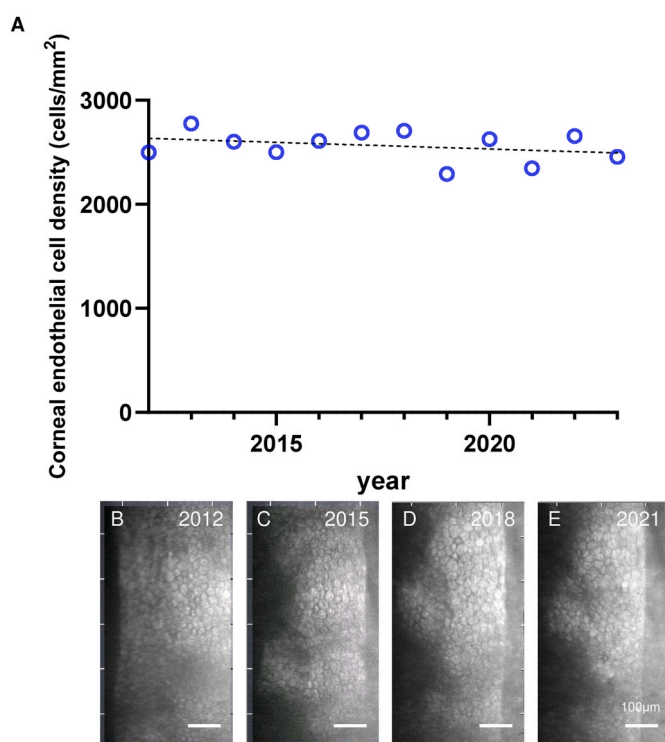


Fig. 3. Annual central CEC density monitored from the initial visit through twelve years later. This analysis was conducted using non-contact specular microscopy images (EM-4000 Tomey Corporation) (A). The image at the initial visit in 2012 (B), 2015 (C), 2018 (D), and 2021 (E). CEC density was 2499, 2601, 2609, and 2706 cells/mm², respectively.

Funding/support

None to report.

Authorship

All authors attest that they meet the current ICMJE criteria for

authorship.

CRedit authorship contribution statement

Yasufumi Tomioka: Writing – original draft, Data curation, Conceptualization. **Hiroshi Tanaka:** Data curation. **Chie Sotozono:** Writing – original draft, Supervision. **Shigeru Kinoshita:** Writing – review & editing, Supervision.

Declaration of competing interest

The authors declare that they have no known competing financial interests or personal relationships that could have appeared to influence the work reported in this paper.

References

- Levin LA, Kaufman PL, Alm A, Adler FH. *Adler's Physiology of the Eye*. eleventh ed. Saunders/Elsevier; 2011:71–130.
- Joyce NC. Proliferative capacity of the corneal endothelium. *Prog Retin Eye Res*. 2003;22(3):359–389.
- Bourne WM. Clinical estimation of corneal endothelial pump function. *Trans Am Ophthalmol Soc*. 1998;96:229–239. ; discussion 239–242.
- Matsuda M, Sawa M, Edelhauser HF, Bartels SP, Neufeld AH, Kenyon KR. Cellular migration and morphology in corneal endothelial wound repair. *Invest Ophthalmol Vis Sci*. 1985;26(4):443–449.
- Brown SI, McLean JM. Peripheral corneal edema after cataract extraction. A new clinical entity. *Trans Am Acad Ophthalmol Otolaryngol*. 1969;73:465–469.
- Tuft SJ, Kerr Muir M, Sherrard ES, Buckley RJ. Peripheral corneal edema following cataract extraction (Brown-McLean syndrome). *Eye*. 1992;6(Pt 5):502–505.
- Gothard TW, Hardten DR, Lane SS, Doughman DJ, Krachmer JH, Holland EJ. Clinical findings in Brown-McLean syndrome. *Am J Ophthalmol*. 1993;115(6):729–737.
- Reed JW, Cain LR, Weaver RG, Oberfeld SM. Clinical and pathologic findings of aphakic peripheral corneal edema: Brown-McLean syndrome. *Cornea*. 1992;11(6):577–583.
- Kam KW, Jhanji V, Young AL. Brown-McLean syndrome. *BMJ Case Rep*. 2013. <https://doi.org/10.1136/bcr-2013-201280>.
- Lim LT, Tarafdar S, Collins CE, Ramamurthi S, Ramaesh K. Corneal Endothelium in Brown-McLean syndrome: in-vivo confocal microscopy finding. *Semin Ophthalmol*. 2012;27(1-2):6–7.
- Vote BJ, Grupcheva CN, Ormonde SE, McGhee CN. In vivo confocal microstructural analysis and surgical management of Brown-McLean syndrome associated with spontaneous crystalline lens luxation. *J Cataract Refract Surg*. 2003;29(3):614–618.
- Tanaka H, Okumura N, Koizumi N, Sotozono C, Sumii Y, Kinoshita S. Panoramic view of human corneal endothelial cell layer observed by a prototype slit-scanning wide-field contact specular microscope. *Br J Ophthalmol*. 2017;101(5):655–659.

13. Hoffer KJ. Vertical endothelial cell disparity. *Am J Ophthalmol.* 1979;87(3):344–349.
14. Azen SP, Hurt A, Steel D, et al. Effects of the Shearing posterior chamber intraocular lens on the corneal endothelium. *Am J Ophthalmol.* 1983;95(6):798–802.
15. Sampaolesi R, Argento C. Scanning electron microscopy of the trabecular meshwork in normal and glaucomatous eyes. *Invest Ophthalmol Vis Sci.* 1977;16(4):302–314.