

Diagnostic dilemma: Leber's hereditary optic neuropathy in a 70-year-Old woman

Alexandra Pietraszkiewicz^a, Azraa Ayesha^a, Kathleen B. Digre^{a,b}, Judith EA. Warner^{a,b}, Meagan D. Seay^{a,b}, Alison V. Crum^{a,b}, Bradley J. Katz^{a,b,*}

^a Department of Ophthalmology and Visual Sciences, John A Moran Eye Center, University of Utah Health, Salt Lake City, UT, USA

^b Department of Neurology, University of Utah Health, Salt Lake City, UT, USA

ARTICLE INFO

Keywords:

Leber's hereditary optic neuropathy
Mitochondrial disease
Optic neuropathy
Normal tension glaucoma

ABSTRACT

Purpose: Reports of atypical cases have increased awareness that Leber's hereditary optic neuropathy (LHON) is not solely a disease of young men. Here, we present a case of a 70-year-old woman who presented with bilateral sequential loss of vision, and, after several diagnostic dilemmas, was ultimately found to have LHON.

Observations: Our patient presented with a one-month history of progressive central vision loss in the right eye. Her visual acuities were 20/200-1 and 20/25-2. She had no afferent pupillary defect and intraocular pressures were normal. Fundus examination revealed cup-to-disc ratios of 0.9 and 0.7 with an inferior notch on the right. Visual fields showed superior arcuate and cecentral depressions on the right and an inferior nasal step on the left. Ocular coherence tomography showed bilateral, superior and inferior retinal nerve fiber layer thinning. She was diagnosed with normal-tension glaucoma. Laboratory studies and neuroimaging were unremarkable. One month later, she presented with new central vision loss in the left eye. Ocular coherence tomography revealed new, mild optic nerve swelling in the left eye. Due to concern for an acute-on-chronic process, she was hospitalized and treated with intravenous steroids and later plasmapheresis with modest improvement. An extensive laboratory evaluation, lumbar puncture, temporal artery biopsy, and PET CT were normal. Mitochondrial genetic testing was ordered. After a six-week delay, the results revealed a pathogenic variant at mitochondrial position 11778, consistent with a diagnosis of LHON. She began treatment with idebenone. At the most recent visit, her vision had improved to 20/40 and 20/30.

Conclusions and importance: LHON is typically not part of the initial differential diagnosis of an optic neuropathy in patients outside the typical demographic. As genetic testing has become more widely available, clinicians should consider including LHON in their differential diagnosis of any optic neuropathy, especially if other, more common causes have been ruled out.

1. Introduction

Reports of atypical cases have increased awareness that Leber's hereditary optic neuropathy (LHON) is not solely a disease of young men. We present a case of a 70-year-old woman who presented with bilateral sequential loss of vision, and, after several diagnostic dilemmas, was ultimately found to have LHON.

2. Case report

In June 2022, a 70-year-old woman presented with a one-month

history of slowly progressive central vision loss in the right eye. She reported a right-sided headache since having COVID-19 in December 2021. Her past medical history included hypertension, irritable bowel syndrome, and a pituitary adenoma that had been resected in 1980 without chiasmal involvement. She did not smoke or drink alcohol. There was no family history of blindness. Her best-corrected visual acuities were 20/200-1 and 20/25-2. She had normal pupils and an afferent pupillary defect was not noted by the technician prior to dilation. Intraocular pressures were 12 mm Hg and 16 mm Hg. Dilated fundus examination revealed cup-to-disc ratios of 0.9 and 0.7 with an inferior notch on the right. Perimetry showed superior arcuate and

* Corresponding author. Department of Ophthalmology and Visual Sciences, John A Moran Eye Center, University of Utah Health, 65 N Mario Capecchi Drive, Salt Lake City, UT, 84132, USA.

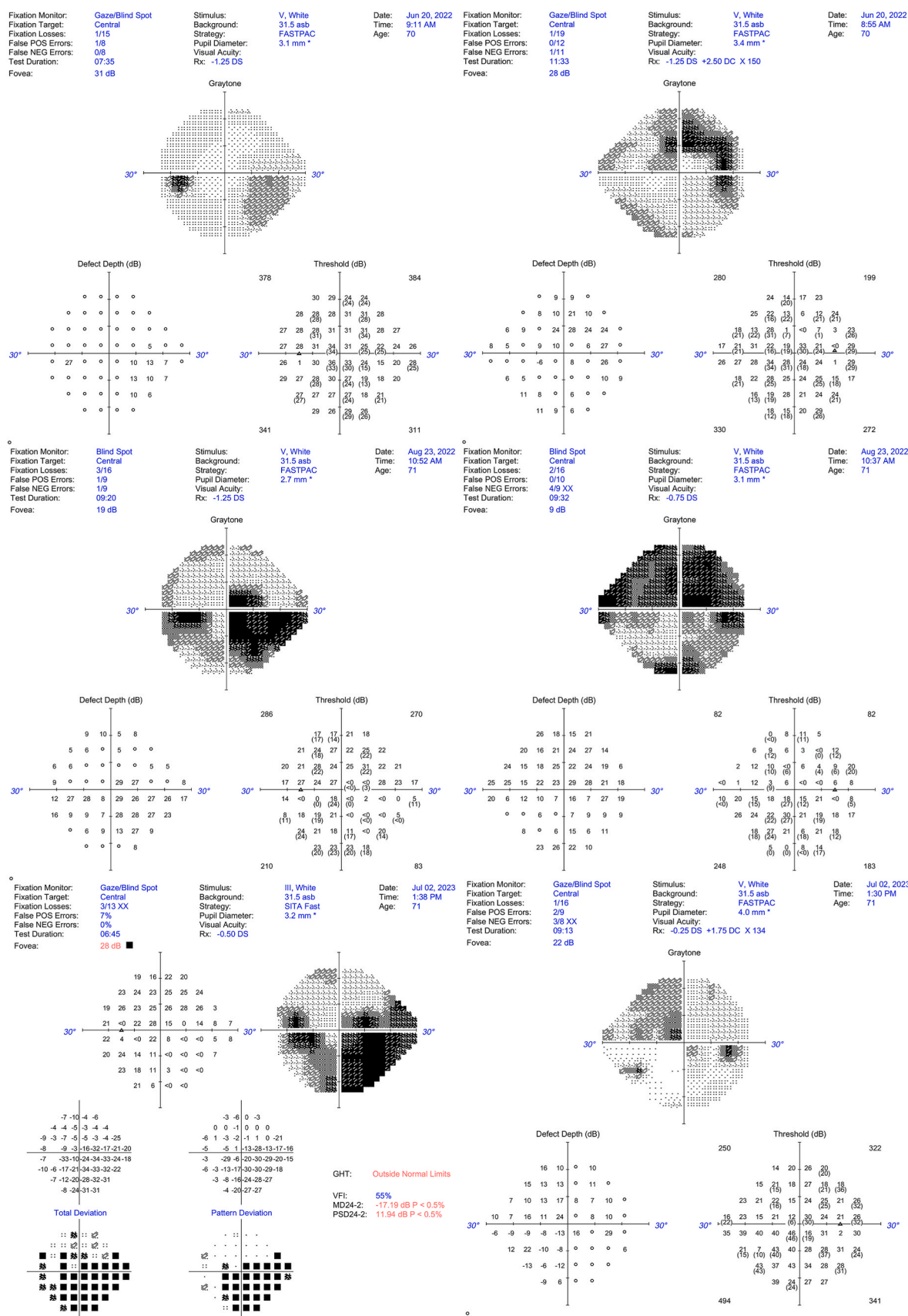
E-mail address: bradley.katz@hsc.utah.edu (B.J. Katz).

<https://doi.org/10.1016/j.ajoc.2024.102143>

Received 9 February 2024; Received in revised form 4 July 2024; Accepted 14 August 2024

Available online 22 August 2024

2451-9936/© 2024 The Authors. Published by Elsevier Inc. This is an open access article under the CC BY-NC-ND license (<http://creativecommons.org/licenses/by-nc-nd/4.0/>).



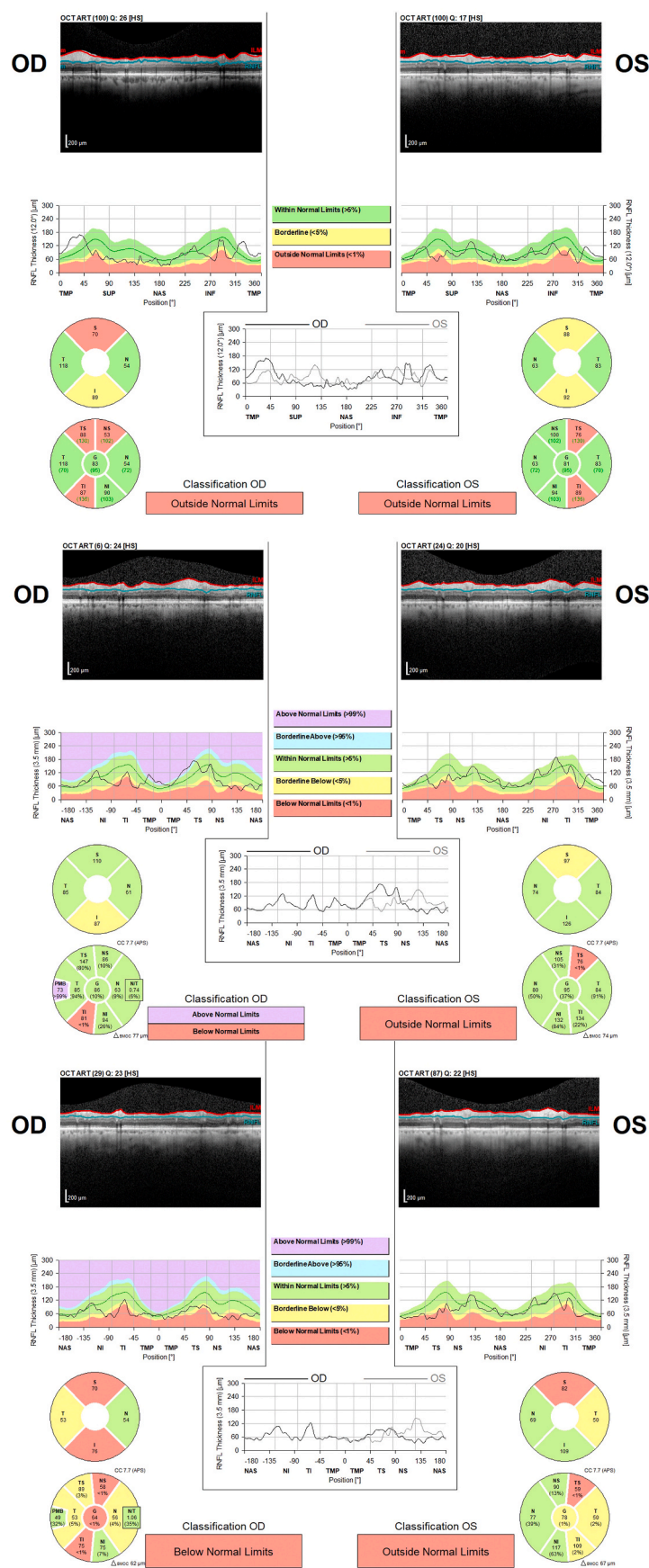


Fig. 2. OCT RNFL at presentation, 2 months, and 1 year showing bilateral superior and inferior thinning, worse on the right. At 2 months, there was increased average RNFL compared to baseline, indicative of mild optic nerve swelling in the right eye. At 1 year, there was progressive thinning bilaterally.

cecocentral defects in the right eye and an inferior nasal step in the left eye (Fig. 1). Optical coherence tomography (OCT) showed bilateral, superior and inferior retinal nerve fiber layer (RNFL) thinning (Fig. 2). She was diagnosed with normal-tension glaucoma with new central involvement. Laboratory studies revealed normal blood count, normal erythrocyte sedimentation rate, and mildly elevated c-reactive protein of 1.0 (normal 0.0–0.8 mg/dl). MRI brain and orbits with contrast showed no recurrence of her pituitary adenoma and no abnormal enhancement of the optic nerves. Ultrasound of the temporal arteries showed normal flow by color doppler. She was started on combination brimonidine/timolol eye drops twice daily.

One month later, she presented with new central vision loss in the left eye. Visual acuities were 20/200 in each eye. Automated perimetry revealed worsening visual field loss in the left eye (Fig. 1) and OCT showed an increased average RNFL thickness in the left eye, indicating mild optic nerve swelling (Fig. 2). Due to concern for an inflammatory optic neuropathy on top of open angle glaucoma, she was hospitalized and received a three-day course of IV methylprednisolone. Laboratory evaluations for nutritional, toxic, infectious, and autoimmune etiologies were normal. Lumbar puncture and temporal artery biopsy were both normal. PET CT and paraneoplastic antibodies were also normal. She was discharged with modest improvement in signs and symptoms.

Four days after her discharge, she presented with further vision loss in each eye. She was re-admitted to the hospital where she received another course of IV steroids and five sessions of plasmapheresis followed by intravenous immunoglobulin.

During her initial hospitalization, because her presentation was not consistent with glaucoma or an inflammatory optic neuropathy, mitochondrial DNA sequencing was ordered. The results were not available for six weeks. When the results became available, sequence analysis and deletion testing of the mitochondrial genome revealed our patient was homoplasmic for a pathogenic variant in the MT-ND4 gene (11778 G > A) which is commonly associated with LHON (NGS performed by GeneDx, Gaithersburg, MD, USA. GeneDx is CLIA certified).

Because our patient had features of normal-tension glaucoma and LHON, she continues to be treated for both conditions, using a combination of intraocular-pressure lowering medications and idebenone 900 mg/day. At her most recent visit, after 24 weeks of treatment with idebenone, visual acuities had improved to 20/40 and 20/30 and her visual field defects (Fig. 1) and retinal nerve fiber layer defects (Fig. 2) were stable.

3. Discussion and conclusions

Reports of atypical cases have increased awareness that LHON is not solely a disease of young men.¹ However, with a reported incidence of only 5–10 % in women harboring pathogenic variants due to incomplete penetrance,² there are even fewer reports of affected older women. In general, late-onset LHON is most commonly caused by the 11778 mutation.³ There may be an increased prevalence of LHON mtDNA mutations in patients diagnosed with normal-tension glaucoma, and morphology of the optic nerve in atrophic stages can be difficult to distinguish clinically.⁴ Clinicians should consider including LHON in their differential diagnosis of any optic neuropathy, especially if other, more common causes have been ruled out. LHON should particularly be considered in patients with rapidly progressive primary open angle or normal tension glaucoma.

Other than a modestly elevated c-reactive protein, this patient's initial inflammatory disease workup was negative. However, we cannot rule out the possibility that IV steroid treatment and plasmapheresis contributed to this patient's favorable visual outcome.

Although patients with 11778 mutations have a poorer visual prognosis compared to patients with 14484 mutations,⁵ control of risk factors should be advised in all cases regardless of genotype due to the potential for recovery. In a review of mutation-independent therapies

for LHON, Chen, Yu-Wai-Man and Newman concluded that treatment with idebenone appears to be effective in improving or stabilizing vision, especially if treatment is initiated early in the disease course and if treatment is continued for a longer duration.⁶ In an expanded access program involving 87 patients, 46.0 % of patients treated with idebenone within 12 months of symptom onset experienced a clinically relevant improvement in acuity (defined as off-chart acuity to on-chart acuity by at least one line or an improvement in on-chart acuity by at least two lines).⁷ These authors recommended treatment for at least 18–24 months.

4. Patient consent

Consent to publish the case report was obtained. This report does not contain any personal information that could lead to the identification of the patient.

CRedit authorship contribution statement

Alexandra Pietraszkiewicz: Writing – review & editing, Writing – original draft, Formal analysis, Data curation, Conceptualization. **Azraa Ayesha:** Writing – review & editing, Writing – original draft, Formal analysis, Data curation, Conceptualization. **Kathleen B. Digre:** Writing – review & editing, Writing – original draft, Formal analysis, Data curation, Conceptualization. **Judith EA. Warner:** Writing – review & editing, Writing – original draft, Formal analysis, Data curation, Conceptualization. **Meagan D. Seay:** Writing – review & editing, Writing – original draft, Formal analysis, Data curation, Conceptualization. **Alison V. Crum:** Writing – review & editing, Writing – original draft, Formal analysis, Data curation, Conceptualization. **Bradley J. Katz:** Writing – review & editing, Writing – original draft, Investigation, Formal analysis, Data curation, Conceptualization.

Declaration of competing interest

The authors declare that they have no known competing financial interests or personal relationships that could have appeared to influence the work reported in this paper.

Acknowledgments and Disclosures

The authors thank Paul Crown, ophthalmic photographer, for assistance with creating the figures. All authors report they have no financial disclosures relevant to the content of this manuscript. All authors attest that they meet the current ICMJE criteria for Authorship. Supported by an unrestricted grant to the Department of Ophthalmology and Visual Sciences from Research to Prevent Blindness, Inc., New York, NY, USA.

References

- Borrut FX, Green WT, Graham EM, Sweeney MG, Morgan-Hughes JA, Sanders MD. Late onset Leber's optic neuropathy: a case confused with ischaemic optic neuropathy. *Br J Ophthalmol*. 1992;76:571–573.
- Yu-Wai-Man P, Turnbull DM, Chinnery PF. Leber hereditary optic neuropathy. *J Med Genet*. 2002;39:162–169.
- Dimitriadis K, Leonhardt M, Yu-Wai-Man P, et al. Leber's hereditary optic neuropathy with late disease onset: clinical and molecular characteristics of 20 patients. *Orphanet J Rare Dis*. 2014;9:158.
- Inagaki Y, Mashima Y, Fuse N, Ohtake Y, Fujimaki T, Fukuchi T. Mitochondrial DNA mutations with Leber's hereditary optic neuropathy in Japanese patients with open-angle glaucoma. *Jpn J Ophthalmol*. 2006;50:128–134.
- Newman NJ, Carelli V, Taiel M, Yu-Wai-Man P. Visual outcomes in leber hereditary optic neuropathy patients with the m.11778G>A (MTND4) mitochondrial DNA mutation. *J Neuro Ophthalmol*. 2020;40:547–557.
- Chen BS, Yu-Wai-Man P, Newman NJ. Developments in the treatment of leber hereditary optic neuropathy. *Curr Neurol Neurosci Rep*. 2022;22:881–892.
- Catarino CB, von Livonius B, Priglinger C, et al. Real-world clinical experience with idebenone in the treatment of Leber hereditary optic neuropathy. *J Neuro Ophthalmol*. 2020;40:558–565.