

Segmental retinal arteritis in a case of presumed bilateral rifabutin-associated hypopyon uveitis

Shefali Sood^a, Jeanette Du^{a,b,*}, Allison Chen^c, Andy Medina^d, Brian K. Do^{a,b}

^a Department of Ophthalmology, Medstar Washington Hospital Center/Georgetown University Hospital, 110 Irving St NW, Washington DC, 20010, USA

^b The Retina Group of Washington, 5454 Wisconsin Ave Suite 650, Chevy Chase, MD, 20815, USA

^c Wright State University Boonshoft School of Medicine, 3640 Colonel Glenn Hwy, Fairborn, OH, 45324, USA

^d Department of Ophthalmology, SUNY Buffalo School of Medicine, 955 Main St, Buffalo, NY, 14203, USA

ARTICLE INFO

Keywords:

Rifabutin-associated uveitis

Segmental retinal arteritis

HIV/AIDS

Hypopyon uveitis

ABSTRACT

Purpose: To describe the presentation and clinical course of bilateral hypopyon uveitis and subsequently diagnosed segmental retinal arteritis in an immunocompromised patient treated with intravitreal and systemic antibiotics while on rifabutin therapy for pulmonary tuberculosis (TB).

Observations: A 63-year-old female from West Africa with a past medical history of HIV/AIDS, hepatitis B, and pulmonary TB presented with pain and acute vision loss in the left eye for two days. She was compliant with her treatment regimen for HIV and maintenance therapy for TB including rifabutin. Ocular examination revealed hypopyon uveitis in the left eye (OS). She was treated with broad spectrum systemic antimicrobials, topical prednisolone acetate, and intravitreal injections of vancomycin, ceftazidime, voriconazole, and ganciclovir, with resolution of hypopyon OS in 3 days. Aqueous sampling and systemic workup were unrevealing for causative infection. Two weeks later, she returned with a nearly identical presentation in the right eye (OD) with hypopyon uveitis and was again treated with intravitreal antibiotics. Anterior segment inflammation OD quickly improved after initiation of topical prednisolone acetate 1 % to reveal segmental retinal arteritis on fundus examination. As aqueous sampling was negative for infectious causes, she was diagnosed with presumed rifabutin associated-hypopyon uveitis in both eyes (OU) and segmental retinal arteritis OD, which has not been described previously with rifabutin use. Rifabutin was discontinued and there were no recurrences of uveitis over nine months of follow-up.

Conclusions and importance/implications: Uveitis is an uncommon dose-related toxicity of rifabutin therapy. Segmental retinal arteritis (SRA) may be a rare finding when there is posterior segment involvement, especially in patients with concurrent TB infection. This report highlights a case of delayed bilateral hypopyon-uveitis and expands the presentation to include SRA. Patients treated with rifabutin should be counseled on signs and symptoms of uveitis. Development of rifabutin-associated uveitis may require medication discontinuation.

1. Introduction

Rifabutin-associated uveitis is a well-documented dose-related medication toxicity that typically manifests as anterior uveitis with or without hypopyon.^{1,2} Uveitis can sequentially affect both eyes in patients on rifabutin for treatment or prophylaxis of pulmonary *Mycobacterium avium* complex or *Mycobacterium tuberculosis* infection.³ Rarely, the condition induces a dense vitritis or panuveitis mimicking endophthalmitis.^{2,4} While the entity was initially described in patients with human immunodeficiency virus (HIV)/acquired immunodeficiency syndrome (AIDS), it can also occur in immunocompetent people or those

immunosuppressed by other causes.¹ Presentation is commonly associated with high doses of rifabutin, concurrent treatment with cytochrome 3A4 (CYP3A4) inhibitors, or low body weight (<65 kg).^{2,5,6} Retinal involvement is uncommon, with few case reports describing cystoid macular edema (CME), diffuse retinal vasculitis, peripheral vasculitis, or perivascular sheathing.^{7–10} Treatment includes topical steroids, which can result in rapid resolution of the inflammation, and in some cases, drug cessation.^{10,11}

Segmental retinal arteritis (SRA) is a rare finding of focal, segmental plaques in the retinal arteries.¹² It is described in the setting of severe inflammation associated with infectious posterior uveitides, such as

* Corresponding author. The Retina Group of Washington, 5454 Wisconsin Ave Suite 650 Chevy Chase, MD, 20815, USA.

E-mail address: jeanette.du3@gmail.com (J. Du).

<https://doi.org/10.1016/j.ajoc.2024.102170>

Received 4 February 2024; Received in revised form 7 August 2024; Accepted 4 September 2024

Available online 10 September 2024

2451-9936/© 2024 Published by Elsevier Inc. This is an open access article under the CC BY-NC-ND license (<http://creativecommons.org/licenses/by-nc-nd/4.0/>).

tuberculous uveitis, ocular toxoplasmosis, syphilis, and acute retinal necrosis, as well as with inflammatory conditions, such as Behcet's disease and sarcoidosis.^{12–14} We describe a case of presumed bilateral, sequential rifabutin-associated hypopyon uveitis and unilateral SRA in an immunocompromised patient.

2. Case report

A 63-year-old female from West Africa with a medical history of HIV/AIDS, hepatitis B, and *Mycobacterium tuberculosis* (TB) infection presented to our emergency clinic with pain and acute vision loss OS for two days. HIV/AIDS, hepatitis B and pulmonary TB were initially diagnosed and treated four years prior to presentation. Upon initial diagnosis of pulmonary TB, she received six months of treatment with rifabutin and isoniazid followed by nine months of treatment with rifampin and isoniazid. She was compliant with her HIV regimen of dolutegravir 50 mg, emtricitabine 200 mg and tenofovir 300 mg daily. She had a relapse of pulmonary disease seven months prior to her ocular presentation that required maintenance therapy of rifabutin 450 mg, isoniazid 300 mg and pyridoxine 50 mg daily, with which she was compliant. Her body weight was 62.3 kg and three weeks prior to presentation, her CD4 count was 166/mm³ with an HIV viral load of <20 copies/mL.

Examination revealed best-corrected visual acuity (BCVA) of 20/20 OD and light perception (LP) OS, with no relative afferent pupillary defect (rAPD). Intraocular pressure was 9 OD and 8 OS. Ocular examination OD including fundus examination was normal. Slit-lamp examination OS revealed fibrinous anterior chamber reaction with 4+ anterior chamber (AC) cell and flare, pupillary membrane, and 1 mm hypopyon (Fig. 1). There was no view to the left fundus, and ultrasonography OS showed vitritis. Due to concern for endogenous endophthalmitis, she was admitted to the hospital for infectious workup and systemic broad-spectrum antimicrobial therapy, including intravenous vancomycin and cefepime, oral trimethoprim/sulfamethoxazole, and oral valganciclovir. An aqueous sample was sent for bacterial and fungal cultures, as well as viral and toxoplasmosis polymerase chain reaction (PCR) testing. Intravitreal injections of vancomycin 1 mg/0.10 mL, ceftazidime 2.25/0.10 mL, voriconazole 100 µg/0.10 mL, and ganciclovir 4 mg/0.01 mL

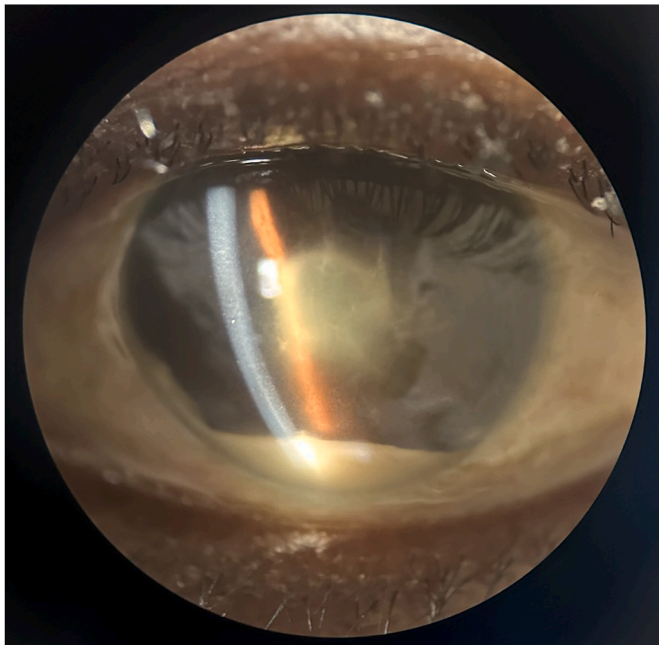


Fig. 1.) Slit lamp photograph of the left eye demonstrates anterior chamber fibrin with pupillary membrane and 1 mm hypopyon.

were administered, and topical therapy with prednisolone acetate 1 % every 2 h and atropine sulfate daily was initiated OS. The hypopyon resolved in 3 days with improvement of visual acuity to 20/30. There was 1+ vitreous cell and haze noted after dissolution of the pupillary membrane. She was maintained on prednisolone acetate four times a day in the left eye. Her CD4 count was 199/mm³ with a controlled viral load. Her AST was mildly elevated at 49 (range 0–33) and ALT was within normal limits at 21 (range 10–49). She had no signs of cirrhosis or other liver damage at any point in her clinical course. Chest imaging showed interval improvement of her known pulmonary disease. Aqueous sampling and other systemic workup were unrevealing for other infection.

Two weeks after her initial presentation, she returned with a nearly identical picture in the right eye, presenting with a hypopyon uveitis. BCVA was LP OD and 20/30 OS. Anterior segment exam OD showed fibrinous anterior chamber reaction with 4+ AC cell and flare, pupillary membrane, and 1.5 mm hypopyon. There was no view to the right fundus and ultrasonography showed vitritis OD. The left fundus had improving vitreous consolidation near the inferior arcade and a single cotton wool spot with CME on optical coherence tomography (OCT) (Fig. 2A). She received the same intravitreal antibiotic and antiviral treatments as was administered for the left eye, followed by topical prednisolone acetate every 2 h. She did not receive additional systemic antimicrobial treatment. Once the inflammation improved, fundus exam OD became notable for diffuse white plaques along the retinal arteries in all four quadrants (Fig. 3A and B). Arteriovenous phase fluorescein angiogram (FA) showed early hypofluorescence of the lesions and normal arterial filling (Fig. 3C). Late phase FA showed progressive staining, without retinal non-perfusion or vascular leakage associated with the plaques (Fig. 3D). There was late petaloid leakage consistent with CME, which was also appreciated on OCT (Fig. 2B).

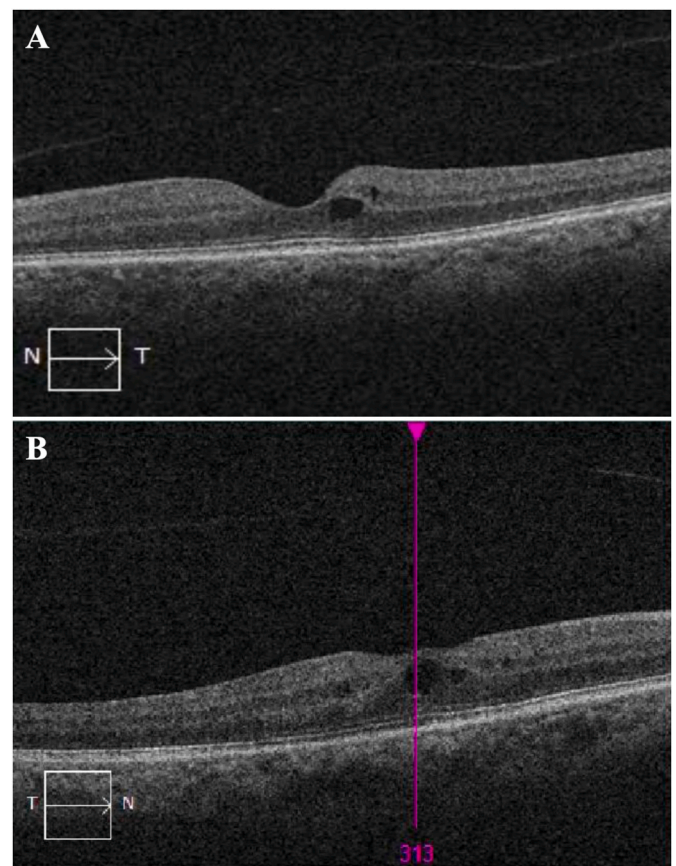


Fig. 2. A) Optical Coherence Tomography (OCT) of the left eye with cystoid macular edema (CME). B) OCT of the right eye with CME.

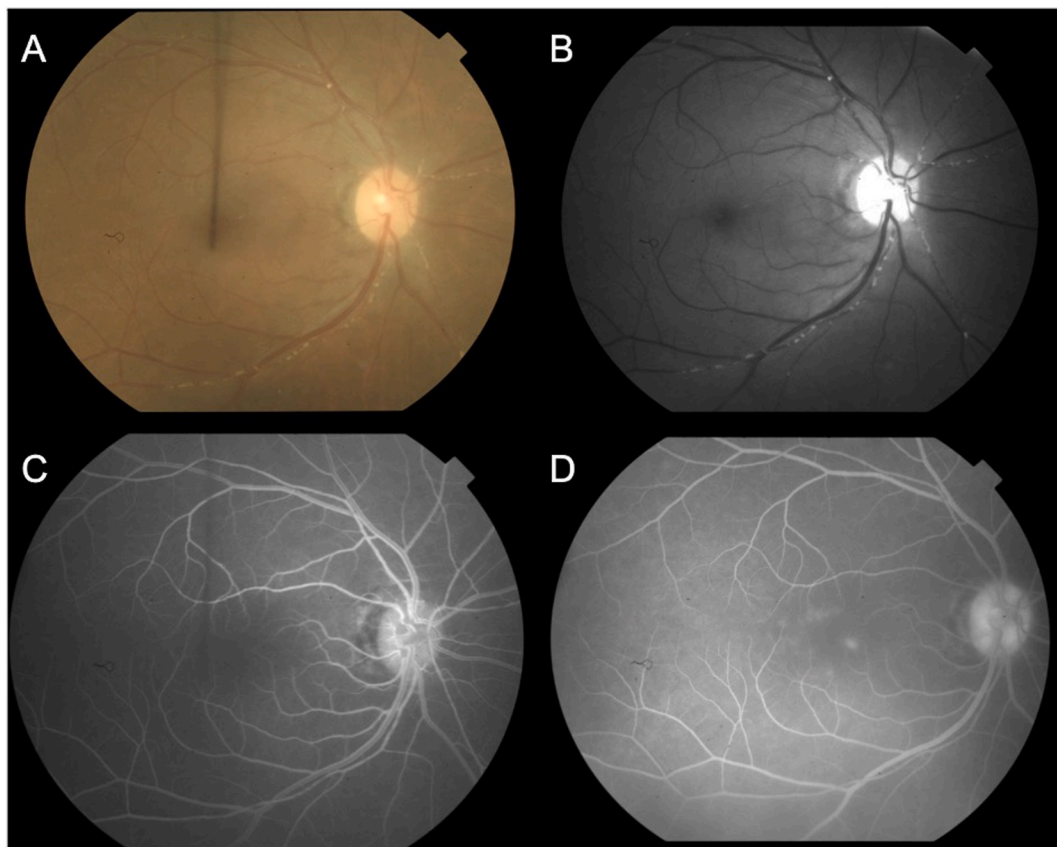


Fig. 3. A) Standard fundus photo shows yellow-white deposits distributed diffusely along the retinal arterioles. B) Red free fundus photo highlights the plaques in all four quadrants. C) Arteriovenous phase fluorescein angiography shows early hypofluorescence of the plaques and normal arterial filling. D) Late phase fluorescein angiogram (FA) shows progressive staining, without retinal non-perfusion or vascular leakage associated with the plaques. There is late petaloid leakage consistent with CME. (For interpretation of the references to colour in this figure legend, the reader is referred to the Web version of this article.)

Given that aqueous sampling in both eyes was unrevealing for infection and that she had been on treatment for TB for several months prior to presentation, we diagnosed her with presumed rifabutin-associated hypopyon uveitis OU and segmental retinal arteritis OD. After rifabutin was discontinued, anterior segment inflammation and vitritis resolved OU and topical prednisolone was tapered over two months. The patient remained 20/30 in both eyes. The plaques persisted for two months after resolution of uveitis, and she had no recurrences over nine months of follow-up.

3. Discussion

Hypopyon uveitis has a broad differential that includes a wide range of infectious, inflammatory and autoimmune causes.¹⁵ Given our patient's history of HIV/AIDS, she was treated broadly for infectious etiologies at presentation. She was already on long term therapy for her known pulmonary TB, and systemic workup and aqueous sampling ruled out other infections. We had low suspicion for an immune reactivation uveitis (IRU) as she had no lapses in antiretroviral treatment, maintained a CD4 count well above 150 for years, and had no history of cytomegalovirus (CMV) retinitis.^{16–18} The uveitis initially affecting her left eye improved with topical steroids, but she developed a similar uveitis of the right eye that required rifabutin cessation for resolution. With other infectious etiologies excluded, we presumed that her presentation was primarily a drug-associated inflammation, especially as she had a rapid and sustained improvement after medication cessation.^{4,7}

For patients with rifabutin-associated uveitis, it has been noted that those treated for active infection have more severe inflammation

compared to those treated for prophylaxis, suggesting that immunogenicity of *Mycobacterium tuberculosis* could play a role.¹⁰ Notably, our patient had a relapse of pulmonary TB infection for which she had resumed treatment with rifabutin six months prior to presentation with uveitis. Ang et al. report that patients with latent TB on antitubercular therapy (ATT) for nine months have an 11-fold reduction in tubercular uveitis recurrence after treatment with ocular and systemic steroids.^{22,23} Multani et al. report that progressive intraocular inflammation after initiation of ATT occurred in only 24.5 % of cases in a highly endemic setting.²⁴ While TB infection is unlikely to be the primary etiology of uveitis in our patient who was on antitubercular therapy (ATT), tubercular uveitis can also be an immune-mediated hypersensitivity reaction to mycobacterial antigens in the absence of active disease.^{25,26} Thus, post-infectious inflammation in addition to a rifabutin-associated drug reaction could have culminated in her presentation.

Ancillary microbiology testing can support a clinical diagnosis of ocular TB, but we did not culture nor perform PCR analysis for *Mycobacterium tuberculosis* on our patient's aqueous samples. Diagnosis by microbiology testing is challenging as cultures and PCR results are often negative and have low sensitivity.^{19–21} The etiology of ocular TB stemming from direct mycobacterial infection versus a hypersensitivity reaction further complicates the interpretation of aqueous sampling results.¹⁹ In our patient's case, the treated status of her known pulmonary TB makes an inflammatory response to mycobacterial antigens a more likely component of her uveitis than active TB infection.

The development of SRA lends support to the possibility that tubercular hypersensitivity may contribute to a severe form of rifabutin-associated uveitis. To our knowledge, this is one of the few cases in the literature describing rifabutin-associated hypopyon with concurrent

retinal pathology and the first case reporting an association with SRA. The plaques in SRA are hypothesized to represent immune deposits along the vessel wall, arteriosclerosis, or migratory inflammatory exudates; however, no histopathological correlation has been made.¹⁴ Multimodal imaging studies implicate that the lesions localize to the endothelial or medial vessel wall, sparing the full-thickness vessel wall and lumen.^{14,27} In line with these descriptions, we observed that the lesions in our patient were not associated with leakage or perfusion defect on FA. SRA most commonly develops in cases of posterior uveitis and is known to be associated with tubercular uveitis.¹⁹

There are few prior reports of rifabutin-associated uveitis with retinal vasculopathy, but none describe lesions of the vasculature consistent with SRA. Chaknis et al. described inferior vitreous opacities in three patients with AIDS, one of whom also had perivascular retinal infiltrates.⁸ Arevalo et al. reported retinal vasculopathy in a patient with severely deficient CD4 count of 4 cells/mm³.⁹ Skolik et al. reported panuveitis with retinal vasculitis in four patients with active TB, three of whom had CD4 counts <100 cells/mm³.¹⁰ Bilateral hypopyon, macular edema, and retinal vasculitis were described in an immunosuppressed 17-year-old female with acute myeloid leukemia.⁷ Although our patient had no active vasculitis by the time a sufficient view of the right fundus was possible, development of SRA reflects that significant inflammation involved the posterior segment. Compared to the cases above, her relatively stable immune status and history of TB infection may have allowed for development of SRA, which always occurs in the setting of severe intraocular inflammation.

Rifabutin-associated uveitis occurs with medication dosages ranging widely from 300 to 1800 mg daily, but patients can develop uveitis on lower doses of 300–600 mg daily when treated concurrently with CYP450 inhibitors such as clarithromycin or fluconazole.⁵ Drug interactions may elevate serum rifabutin concentrations, leading to a dose-related medication toxicity.²⁸ High relative doses in the setting of low body weight (<50 kg) or CYP inhibitor co-therapy are thus hypothesized to contribute to uveitis severity. Toomey et al. reported on a patient with well-controlled HIV and non-alcoholic steatohepatitis, who developed bilateral hypopyon panuveitis while taking cobicistat and rifabutin 300 mg daily.²⁹ In addition to CYP inhibitor co-therapy, they postulated that severe inflammation occurred due to concurrent liver pathology. Our patient's case is notable for a moderate rifabutin dose of 450 mg for her body weight of 62.3 kg. Her other medications isoniazid, emtricitabine, tenofovir and dolutegravir are not known to impact rifabutin levels.^{30,31} While she had a history of hepatitis B, there was no evidence of liver damage or cirrhosis like the patient reported by Toomey et al.²⁹

Lastly, our case demonstrates that the onset of uveitis can be delayed after initiation of rifabutin therapy. One series reported that the median time to presentation of uveitis was 79 days after starting rifabutin therapy, but there are other cases of symptom onset over seven months later.^{2,32} While our patient was treated with rifabutin years prior, stable therapy at a dose of 450 mg daily was instituted six months prior to her presentation with uveitis. The degree of inflammation and vision loss affecting our patient was severe and required cessation of rifabutin after infectious causes were excluded. As is typical for rifabutin-associated uveitis, she responded well to topical steroids; however, only discontinuation of the medication allowed for full resolution.

4. Conclusion

Rifabutin-associated hypopyon uveitis may present in a delayed manner in patients with well-controlled HIV on conservative doses of rifabutin for prophylaxis or treatment of TB. While medications like clarithromycin and fluconazole may decrease the threshold for drug toxicity, uveitis can manifest in the absence of such therapy. Immunogenicity of *Mycobacterium tuberculosis* may play a role in cases of severe inflammation and SRA can be a rare associated finding. Patients taking rifabutin should be counseled on the signs and symptoms of uveitis, and

encouraged to seek ophthalmologic care should they arise. Screening fundus examinations may also be prudent to assess for retinal complications. Discontinuation of rifabutin may be necessary for resolution of the condition.

Patient consent

Written consent to publish this case has not been obtained. This report does not contain any personal identifying information.

Funding

No funding or grant support.

CRedit authorship contribution statement

Shefali Sood: Writing – review & editing, Writing – original draft, Data curation, Conceptualization. **Jeanette Du:** Writing – review & editing, Writing – original draft, Supervision, Data curation, Conceptualization. **Allison Chen:** Writing – review & editing, Writing – original draft, Data curation. **Andy Medina:** Writing – review & editing, Data curation. **Brian K. Do:** Writing – review & editing, Supervision, Conceptualization.

Declaration of competing interest

The authors declare that they have no known competing financial interests or personal relationships that could have appeared to influence the work reported in this paper.

Acknowledgements

None.

References

- Bhagat N, Read RW, Rao NA, Smith RE, Chong LP. Rifabutin-associated hypopyon uveitis in human immunodeficiency virus-negative immunocompetent individuals. *Ophthalmology*. 2001;108(4):750–752. [https://doi.org/10.1016/s0161-6420\(00\)00586-8](https://doi.org/10.1016/s0161-6420(00)00586-8).
- Saran BR. Rifabutin-associated uveitis. *Ann Pharmacother*. 1997;31(11):1405. <https://doi.org/10.1177/106002809703101121>.
- Khan MA, Singh J, Dhillon B. Rifabutin-induced uveitis with inflammatory vitreous infiltrate. *Eye*. 2000;14(Pt 3A):344–346. <https://doi.org/10.1038/eye.2000.85>. Pt 3A.
- Saha N, Bansal S, Bishop F, McWhinney P. Bilateral hypopyon and vitritis associated with rifabutin therapy in an immunocompetent patient taking itraconazole. *Eye*. 2009;23(6):1481. <https://doi.org/10.1038/eye.2008.240>, 10.1038/eye.2008.240.
- Tseng AL, Walmsley SL. Rifabutin-associated uveitis. *Ann Pharmacother*. 1995;29(11):1149–1155. <https://doi.org/10.1177/106002809502901114>.
- Shafraun SD, Singer J, Zarowny DP, et al. Determinants of rifabutin-associated uveitis in patients treated with rifabutin, clarithromycin, and ethambutol for mycobacterium avium complex bacteremia: a multivariate analysis. canadian HIV trials network protocol 010 study group. *J Infect Dis*. 1998;177(1):252–255. <https://doi.org/10.1086/517366>.
- Smith WM, Reddy MG, Hutcheson KA, Bishop RJ, Sen HN. Rifabutin-associated hypopyon uveitis and retinal vasculitis with a history of acute myeloid leukemia. *J Ophthalmic Inflamm Infect*. 2012;2(3):149–152. <https://doi.org/10.1007/s12348-012-0059-9>.
- Chaknis MJ, Brooks SE, Mitchell KT, Marcus DM. Inflammatory opacities of the vitreous in rifabutin-associated uveitis. *Am J Ophthalmol*. 1996;122(4):580–582. [https://doi.org/10.1016/s0002-9394\(14\)72124-5](https://doi.org/10.1016/s0002-9394(14)72124-5).
- Arevalo JF, Russack V, Freeman WR. New ophthalmic manifestations of presumed rifabutin-related uveitis. *Ophthalmic Surg Laser*. 1997;28(4):321–324.
- Skolik S, Willerman F, Caspers LE. Rifabutin-associated panuveitis with retinal vasculitis in pulmonary tuberculosis. *Ocul Immunol Inflamm*. 2005;13(6):483–485. <https://doi.org/10.1080/09273940509051115>.
- Vats S, Agrawal M, Srikanth S, Kumar P, Goenka R. Low-dose rifabutin-induced uveitis with premature occurrence: a case series of rare presentation. *Indian Journal of Ophthalmology - Case Reports*. 2022;2(2). https://journals.lww.com/ijog/fulltext/2022/02020/low_dose_rifabutin_induced_uveitis_with_premature.31.aspx.
- Orzalessi N, Ricciardi L. Segmental retinal periarthritis. *Am J Ophthalmol*. 1971;72(1):55–59. [https://doi.org/10.1016/0002-9394\(71\)91590-x](https://doi.org/10.1016/0002-9394(71)91590-x).

13. Mahjoub A, Ben Abdesslem N, Zaafrane N, et al. Kyrieleis arteritis associated with toxoplasmic retinochoroiditis: a case report. *Ann Med Surg (Lond)*. 2022;78, 103802. <https://doi.org/10.1016/j.amsu.2022.103802>.
14. Tsui E, Leong BCS, Mehta N, et al. Evaluation of segmental retinal arteritis with optical coherence tomography angiography. *Retin Cases Brief Rep*. 2021;15(6): 688–693. <https://doi.org/10.1097/ICB.0000000000000900>.
15. Zaidi AA, Ying G, Daniel E, et al. Hypopyon in patients with uveitis. *Ophthalmology*. 2010;117(2):366–372. <https://doi.org/10.1016/j.ophtha.2009.07.025>.
16. Urban B, Bakunowicz-Lazarczyk A, Michalczyk M. Immune recovery uveitis: pathogenesis, clinical symptoms, and treatment. *Mediat Inflamm*. 2014;2014, 971417. <https://doi.org/10.1155/2014/971417>.
17. Nair N, Sudharshan S, Koladiya NA, Biswas J. Rifabutin induced hypopyon uveitis mimicking endophthalmitis as a manifestation of IRU in patients with HIV. *Indian J Pharmacol*. 2022;54(1):67–68. https://doi.org/10.4103/ijp.ijp_62_22.
18. Gan NY, Teoh SC. Haemorrhagic hypertensive hypopyon uveitis in early immune reactivation uveitis. *Eye*. 2010;24(2):383. <https://doi.org/10.1038/eye.2009.100>.
19. Alvarez GG, Roth VR, Hodge W. Ocular tuberculosis: diagnostic and treatment challenges. *Int J Infect Dis*. 2009;13(4):432–435. <https://doi.org/10.1016/j.ijid.2008.09.018>.
20. Vasconcelos-Santos DV, Zierhut M, Rao NA. Strengths and weaknesses of diagnostic tools for tuberculous uveitis. *Ocul Immunol Inflamm*. 2009;17(5):351–355. <https://doi.org/10.3109/09273940903168688>.
21. La Distia Nora R, Putera I, Khalisha DF, Septiana I, Sitompul R. The diagnostic value of polymerase chain reaction for ocular tuberculosis diagnosis in relation to antitubercular therapy response: a meta-analysis. *Int J Infect Dis*. 2021;110:394–402. <https://doi.org/10.1016/j.ijid.2021.07.075>.
22. Ang M, Chee S. Controversies in ocular tuberculosis. *Br J Ophthalmol*. 2017;101(1): 6–9. <https://doi.org/10.1136/bjophthalmol-2016-309531>.
23. Ang M, Hedayatfar A, Wong W, Chee S. Duration of anti-tubercular therapy in uveitis associated with latent tuberculosis: a case-control study. *Br J Ophthalmol*. 2012;96(3):332–336. <https://doi.org/10.1136/bjophthalmol-2011-300209>.
24. Multani PK, Modi R, Basu S. Pattern of recurrent inflammation following anti-tubercular therapy for ocular tuberculosis. *Ocul Immunol Inflamm*. 2022;30(1): 185–190. <https://doi.org/10.1080/09273948.2020.1772838>.
25. Gupta V, Gupta A, Rao NA. Intraocular tuberculosis—an update. *Surv Ophthalmol*. 2007;52(6):561–587. <https://doi.org/10.1016/j.survophthal.2007.08.015>.
26. Lish A, Berman DH. Tuberculin-triggered panuveitis in a patient recently treated for active pulmonary tuberculosis. *Am J Ophthalmol*. 1993;116(6):771–773. [https://doi.org/10.1016/s0002-9394\(14\)73484-1](https://doi.org/10.1016/s0002-9394(14)73484-1).
27. Pichi F, Veronese C, Lembo A, et al. New appraisals of kyrieleis plaques: a multimodal imaging study. *Br J Ophthalmol*. 2017;101(3):316–321. <https://doi.org/10.1136/bjophthalmol-2015-308246>.
28. Cheng W, Chang C, Lu P, Lin H. Bilateral uveitis associated with concurrent administration of rifabutin and nelfinavir. *Taiwan Journal of Ophthalmology*. 2015;5 (4):187–188. <https://doi.org/10.1016/j.tjo.2014.08.004>. <https://www.sciencedirect.com/science/article/pii/S2211505614000842>.
29. Toomey CB, Lee J, Spencer DB. Rifabutin-cobicistat drug interaction resulting in severe bilateral panuveitis. *Case Rep Ophthalmol*. 2020;11(1):156–160. <https://doi.org/10.1159/000506181>.
30. Martin TCS, Hill LA, Tang ME, Balcombe SM. Tenofovir alafenamide and rifabutin co-administration does not lead to loss of HIV-1 suppression: a retrospective observational study. *Int J Infect Dis*. 2020;100:470–472. <https://doi.org/10.1016/j.ijid.2020.09.1423>.
31. Cottrell ML, Hadzic T, Kashuba ADM. Clinical pharmacokinetic, pharmacodynamic and drug-interaction profile of the integrase inhibitor dolutegravir. *Clin Pharmacokinet*. 2013;52(11):981–994. <https://doi.org/10.1007/s40262-013-0093-2>.
32. Havlir D, Torriani F, Dube M. Uveitis associated with rifabutin prophylaxis. *Ann Intern Med*. 1994;121(7):510–512. <https://doi.org/10.7326/0003-4819-121-7-199410010-00006>.