

# Congenital Bilateral Mid Ureteral Stenosis: A Rare Finding

TANWAR HARSHAWARDHAN VEDPALSINGH<sup>1</sup>, JOSHI AVINASH VIJAY<sup>2</sup>, WAGASKAR VINAYAK GORAKHNATH<sup>3</sup>, BACHHAV MANOJ VILAS<sup>4</sup>, DAGA SUDARSHAN OMPRAKASH<sup>5</sup>

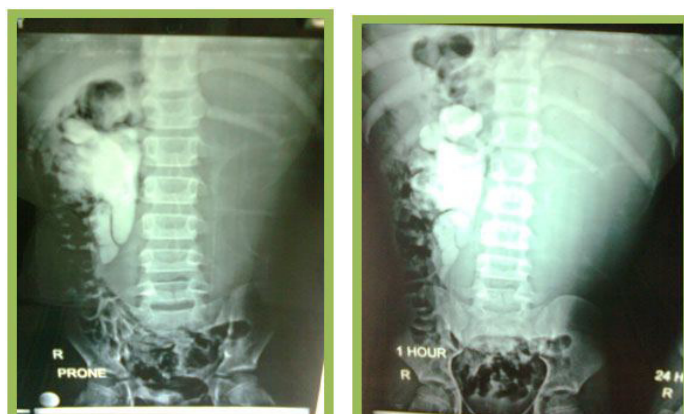
## ABSTRACT

Bilateral congenital mid ureteric stenosis is a very rare entity causing hydroureteronephrosis. The pathophysiology and aetiology of this condition is uncertain. Congenital functional obstruction of the mid ureter has only 17 reported cases, that too of unilateral pathology. We report a case of an 11-year-old male child who was presented with left sided lump in abdomen since one year. On bilateral retrograde ureteropyelography (RGP), bilateral mid ureteric stenosis was documented at the level of pelvic brim. Tc99m Diethylene Triamine Pentacetic Acid (DTPA) scan showed non functioning left kidney and decreased function and retention on right side. We did a left nephroureterectomy and uretero-ureterostomy without tapering over a Double-J stent (DJ), with excision of stenosed segment on right side. Pathological review of the ureteric segments of both sides revealed proximal dilatation with non-specific thickening of the muscular wall of the stenosed segments of ureter. The differential diagnosis must additionally include ureteral valves and fibro epithelial polyps. Important role of intravenous pyelography in such cases must be emphasized to localize the pathology site. In addition, retrograde ureteropyelography is essential in management of this anomaly to delineate the stenosed segment of the ureter preoperatively, so that the surgeon can be well prepared with final plan of management.

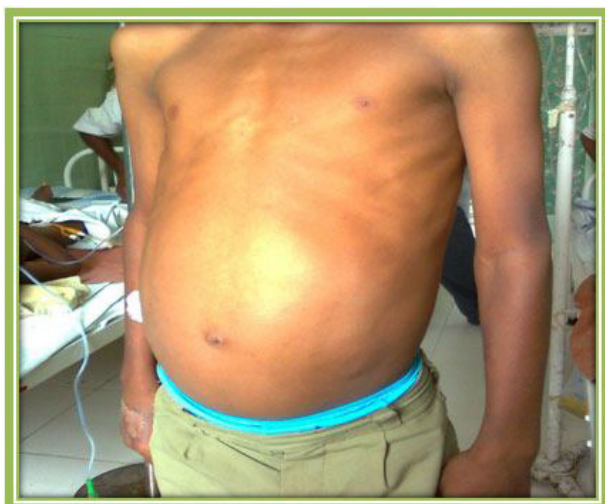**Keywords:** Hydroureteronephrosis, Retrograde ureteropyelography, Uretero-ureterostomy

## CASE REPORT

We report a case of an 11-year-old male child who presented with left sided lump in abdomen since one year. Patient had a history of intermittent constipation but no history of any urinary tract complaints. He had no history of renal stone disease or lithuria in past. He had no significant past medical history or any urological intervention. Renal function test and hemogram was within normal limits. Urine culture for Tuberculosis (TB) and urine for TB polymerase chain reaction (PCR) were negative. On physical examination, left sided lump was palpable in lumbar region extending up to iliac region and crossing midline [Table/Fig-1]. Lump was cystic on palpation and non tender. The ultrasonography (USG) of abdomen revealed bilateral hydronephrosis with proximal hydroureters, massively enlarged left kidney with gross hydronephrosis & thinned out parenchyma and right kidney was moderately hydronephrotic with parenchymal thickness of 12 mm and proximal hydroureter. Bladder on USG was normal. Of note no ureteric dilatation was seen at the level of the bladder. On Intravenous pyelography the



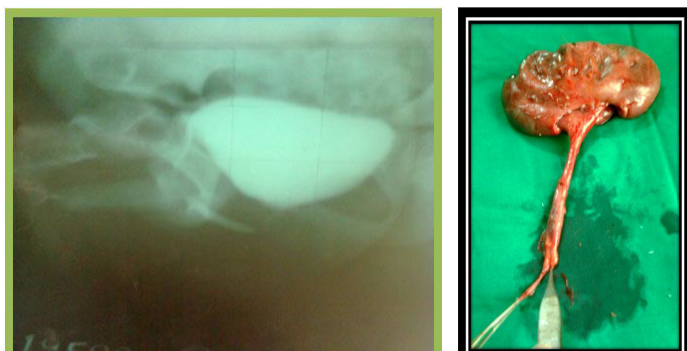
[Table/Fig-2,3]: Intravenous pyelography



[Table/Fig-1]: Clinical image of the left sided lump in abdomen

left kidney was non-functioning with no uptake of contrast, while the right kidney showed moderate hydronephrosis with dilatation of proximal ureter with delayed uptake and retention of contrast, which were suggestive of stricture in right sided mid ureter [Table/Fig-2,3]. Micturating cystourethrogram (MCU) did not show any vesicoureteric reflux or posterior urethral valve. On MCU the bladder was normal [Table/Fig-4]. Tc99m Diethylene Triamine Pentacetic Acid (DTPA) scan showed non-functioning left kidney. Right side kidney showed decreased function with a glomerular filtration rate (GFR) of 40.44ml/min with a 100% retention at two hours with retention in proximal ureter also. On bilateral retrograde ureteropyelography (RGP), bilateral mid ureteric stenosis at the level of pelvic brim was documented. The length of stenosed segment on right side was approximately of 2 to 3 cm and that on left side was 4 to 5 cm. Left sided nephroureterectomy was done through flank incision, approaching extraperitoneally. Intraoperative findings were suggestive of a tight stenotic segment of left midureter with normal calibre ureter distal to it. On right side, extra peritoneal ureteric exploration was performed using a modified Gibson incision. On right side also a similar appearance of the mid ureter was seen but of a shorter length as compared to left side. The stenosed segment

was excised revealing a pin-hole lumen. No valves or polyps were noted intraluminally. Ureter-ureterostomy was performed without tapering over a DJ stent. The post operative course was uneventful with good recovery. Cystoscopic DJ removal was done at 12 wk postoperatively. Follow up ultrasonography at three months showed improvement in hydronephrosis on right side. Follow up DTPA scan after Double-J stent removal showed improvement in drainage pattern of right kidney, with only 40% retention at 20 min [Table/Fig-5]. Pathological review of the ureteric segments of both sides revealed proximal dilatation with non-specific thickening of the muscular wall of the stenosed segments of the ureters. The left kidney histopathology report was consistent with obstructive changes. There were no structural changes in the muscular wall of the ureters on both sides.



**[Table/Fig-4]:** Normal Micturating cystourethrogram (MCU) **[Table/Fig-5]:** Specimen of left hydronephrotic kidney with stenosed mid ureteric segment

## DISCUSSION

Bilateral Congenital mid ureteric stricture is a very rare entity causing hydronephrosis [1], and the diagnosis can be confused with ureteropelvic or ureterovesical junction obstruction. Although ureteral stenosis or strictures most commonly occur in distal ureter and are associated with megaureters, these segments also occur in mid ureters but are rare findings. The pathophysiology and aetiology of this condition is uncertain. Developmentally, narrowing probably results from a disturbance in embryogenesis around the 11<sup>th</sup>-12<sup>th</sup> weeks with disturbed development of mesenchyme contributing to the ureteral musculature. In children with congenital mid ureteral stenosis an association with contra lateral renal agenesis or atrophy has been reported, suggesting possible bilateral aberrant ureteral development [2]. The differential diagnosis must additionally include ureteral valves and fibro epithelial polyps. Congenital mid ureteric obstruction runs a more aggressive natural history than other causes of congenital hydronephrosis [3]. Congenital functional obstruction of the mid ureter has only 17 reported cases, that too of unilateral pathology [4]. After extensive literature search we found only a few case report of bilateral mid ureteral stenosis by Jayanthi VR et al., H Rode et al., and Domenichelli V et al., [1,4,5]. This feature is also suggested by our case where longstanding obstruction resulted in renal impairment. The pathological appearance of mid ureteric obstruction is given by Allen [6], in which the segments were

stenosed but muscle fibres were normal which suggested functional obstruction. Term such as "Midureteral adynamic segment" has been in use for the last few years only [5].

Different theories are postulated for congenital mid ureteric stenosis such as

- 1) Compression by iliac vessels.
- 2) Failure of recanalization of ureter.
- 3) Acquired foetal inflammation of the ureter similar to biliary atresia.

Although ultrasonography may give us anatomic details but it fails to exact localize such unusual pathological lesions. Important role of intravenous pyelography in such cases must be emphasized to localize the pathology site. Magnetic resonance urography (MRU) provides excellent anatomic and functional detail of the collecting system, leading to accurate diagnosis and management of ureteral stricture in children [7]. In addition, retrograde ureteropyelography is essential in management of this anomaly to delineate the stenosed segment of the ureter preoperatively, so that the surgeon can be well prepared with final plan of management. Definitive management includes open or laparoscopic resection of the stenosed segment with uretero-ureterostomy. There are case reports of laparoscopic resection and uretero-ureterostomy for congenital midureteral stricture [8].

## CONCLUSION

There should be a systematic sequence of imaging studies for the evaluation of hydronephrosis such as ultrasonography, micturating cystourethrogram, renal nuclear scan, intravenous pyelography, magnetic resonance urography and if there is diagnostic dilemma then one should proceed with retrograde ureteropyelography (RGP) as it can help us to locate and exactly measure the stenosed segment length. With the help of these diagnostic modalities and their accuracy, we will be able to plan a specific surgical intervention, which can definitely improve our surgical outcome and benefit the patients.

## REFERENCES

- [1] H Rode, M Davies, A van As, A Numanoglu, J Lazarus, R Brown, et al. Bilateral congenital midureteric stricture. *The Internet J of Urol*. 2006;5(1).
- [2] The Kelalis-King-Belman Textbook of Clinical Pediatric Urology, Fifth Edition, edited by Steven G. Docimo; page nub 573.
- [3] Smith BG, Metwalli AR, Leach J, Cheng EY and Kropp BP. Congenital midureteral stricture in children diagnosed with antenatal hydronephrosis. *Urology*. 2004;64(5):1014-19.
- [4] Jayanthi VR, Churchill MB, Thorner PS, McLorie GA, Khoury AE. Bilateral Congenital midureteral adynamic segments. *Urology*. 1995;45:520-23.
- [5] Domenichelli, V., De Biagi, L., Italiano, F., Carfagnini, F., Lavacchini, A., & Federici, S. (). Congenital bilateral mid-ureteral stricture: A unique case. *J pediatric urol*. 2008;4(5):401- 03.
- [6] Allen T. Congenital ureteral strictures. *J Urol*. 1970;104:196-204.
- [7] Grattan-Smith JD, Jones RA, Little S, Kirsch AJ. Bilateral congenital midureteric strictures associated with multicystic dysplastic kidney and hydronephrosis: evaluation with MR urography. *Pediatric radiology*. 2011;41(1):117-20.
- [8] Bhandarkar DS, Lalmalani JG, Shah VJ. Laparoscopic resection and ureteroureterostomy for congenital midureteral stricture. *J Endourol*. 2005;19(2):140-42.

### PARTICULARS OF CONTRIBUTORS:

1. Registrar, Department of Urology, Seth G.S Medical College & KEM Hospital, Mumbai, Maharashtra, India.
2. Assistant Professor, Department of Surgery, Government Medical College, Miraj, Maharashtra, India.
3. Registrar, Department of Urology, Seth G.S Medical College & KEM Hospital, Mumbai, Maharashtra, India.
4. Registrar, Department of Plastic Surgery, Seth G.S Medical College & KEM Hospital, Mumbai, Maharashtra, India.
5. Registrar, Department of Urology, Seth G.S Medical College & KEM Hospital, Mumbai, Maharashtra, India.

### NAME, ADDRESS, E-MAIL ID OF THE CORRESPONDING AUTHOR:

Dr. Tanwar Harshawardhan Vedpalsingh,  
Registrar, Department of Urology, New Building, Seth G.S Medical College & KEM Hospital,  
E Boreges Marg, Parel, Mumbai-400012, Maharashtra, India.  
E-mail : harsh\_bj1@rediffmail.com

**FINANCIAL OR OTHER COMPETING INTERESTS:** None.

Date of Submission: **Mar 09, 2015**  
Date of Peer Review: **Mar 29, 2015**  
Date of Acceptance: **Apr 02, 2015**  
Date of Publishing: **May 01, 2015**